

Obrigada por ver esta apresentação
Gostaríamos de recordar-lhe que esta
apresentação é propriedade do autor.

É-lhe fornecida pela Sociedade Portuguesa
de Nefrologia Pediátrica no contexto do
Curso de Nefrologia Pediátrica, para seu
uso pessoal, tal como submetido pelo
autor

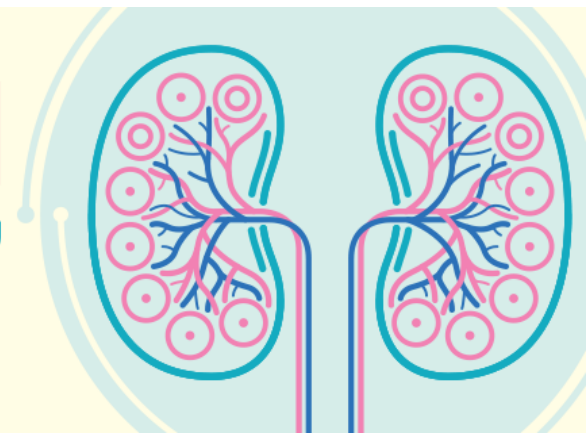© 2017 pelo autor

CURSO DE NEFROLOGIA PEDIÁTRICA

A CRIANÇA COM DOENÇA NEFRO-UROLÓGICA

Sociedade Portuguesa de Nefrologia Pediátrica

26 e 27 2017
JANEIRO LISBOA



Referenciação em

Urologia pediátrica

ribeiro de castro
urologia pediátrica
CMIN – C.H.Porto

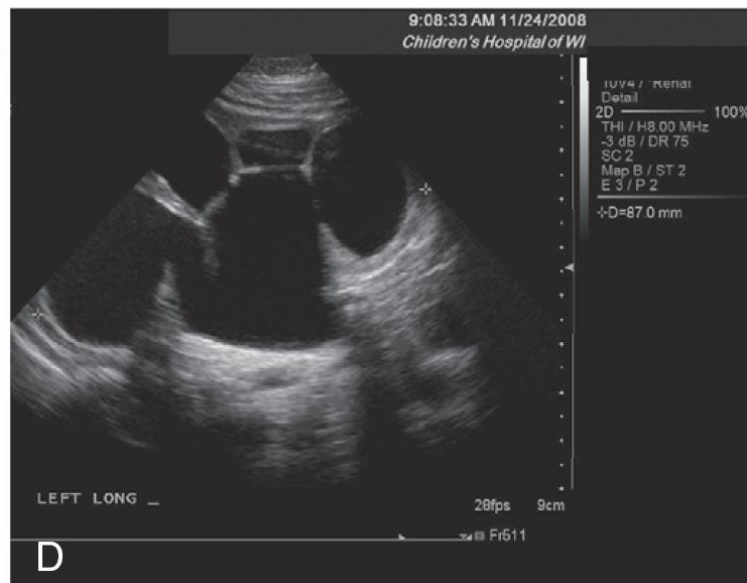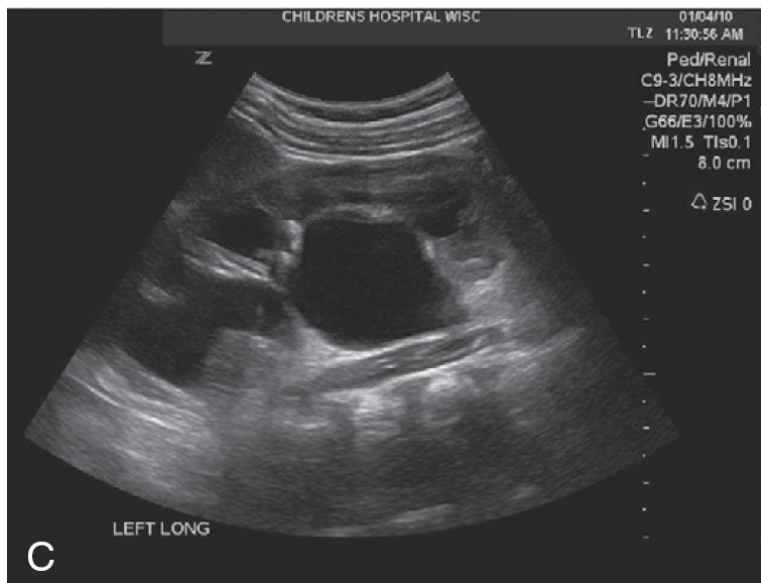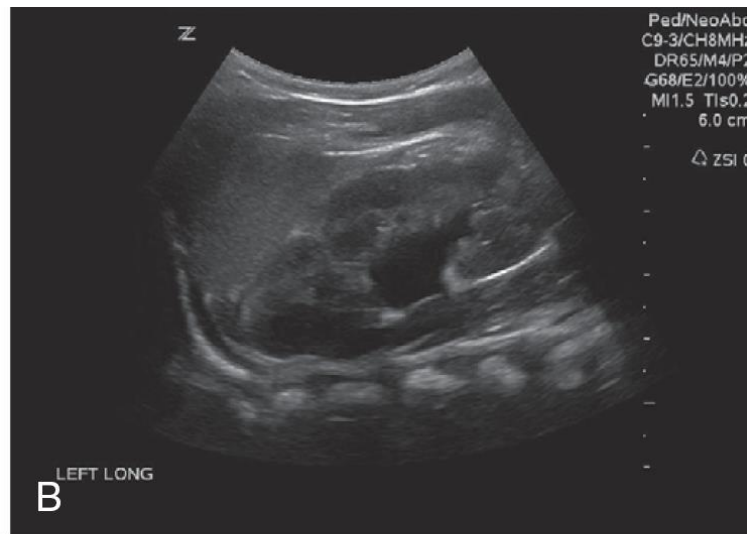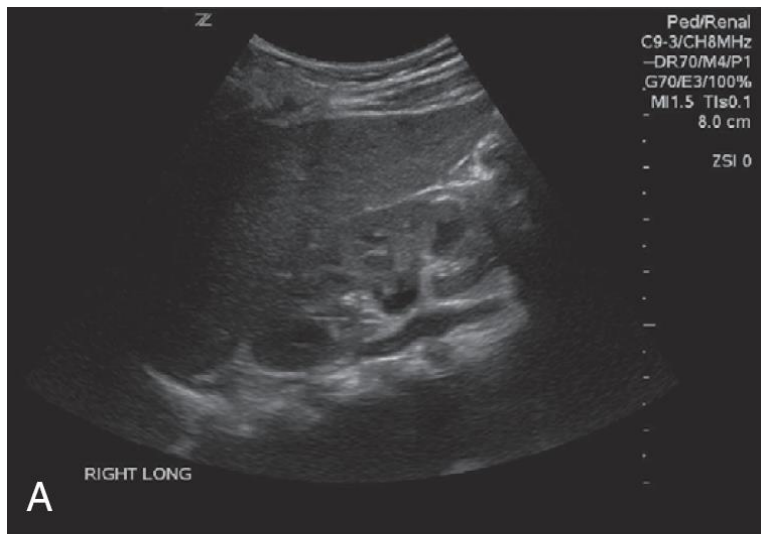O autor declara ausência de potenciais conflitos de interesses
(de acordo com o ponto 24. do documento UEMS 2012/30 “Accreditation of Live
Educational Events by the EACCME”)

urologia pediátrica

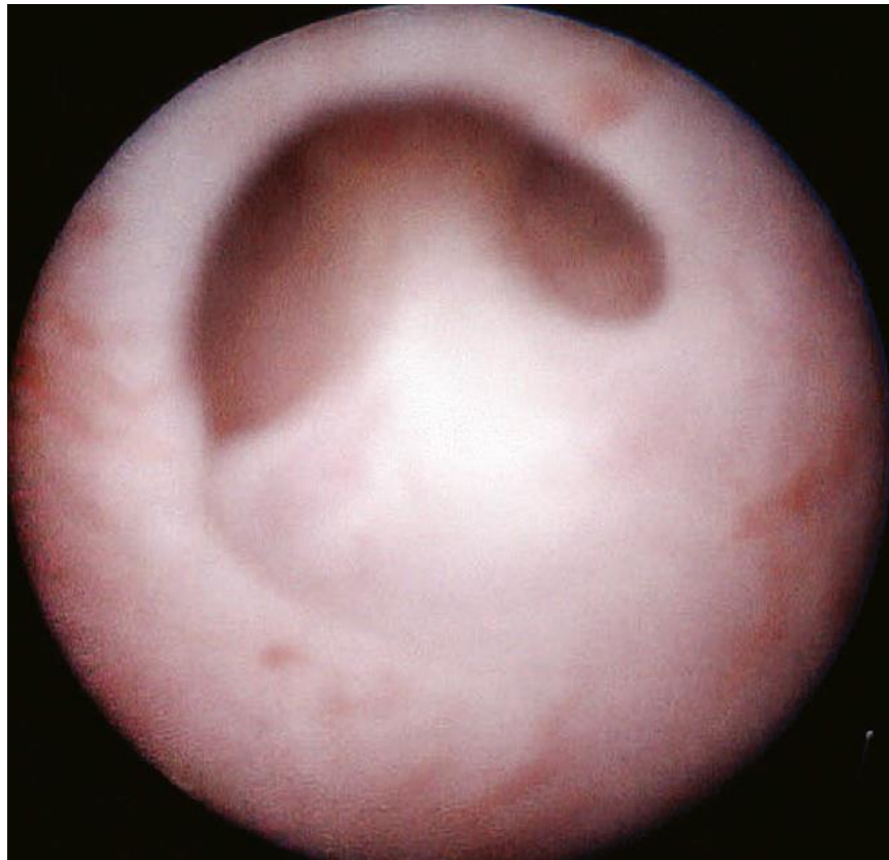
- Diagnóstico pré-natal, urologia fetal
 - Investigação pós-natal
- Malformação congénita urológica
- Uro-fisiologia
 - Bexiga neurogénica
 - Instabilidade vesical
- Uro-litíase
- Trauma
- Oncologia pediátrica
- Transplante renal

Malformações nefro-urológicas diagnóstico pré-natal

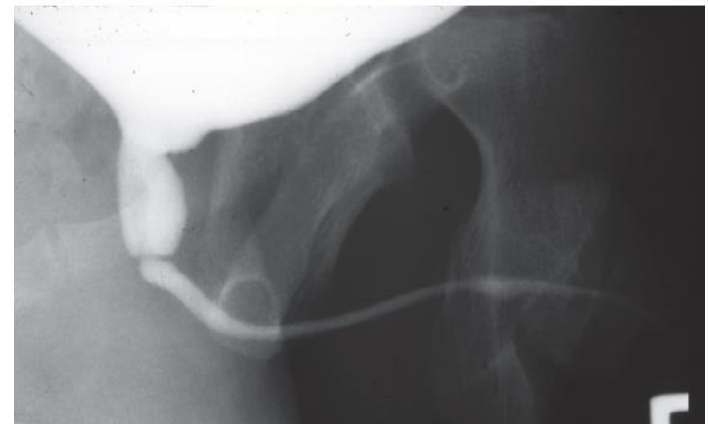
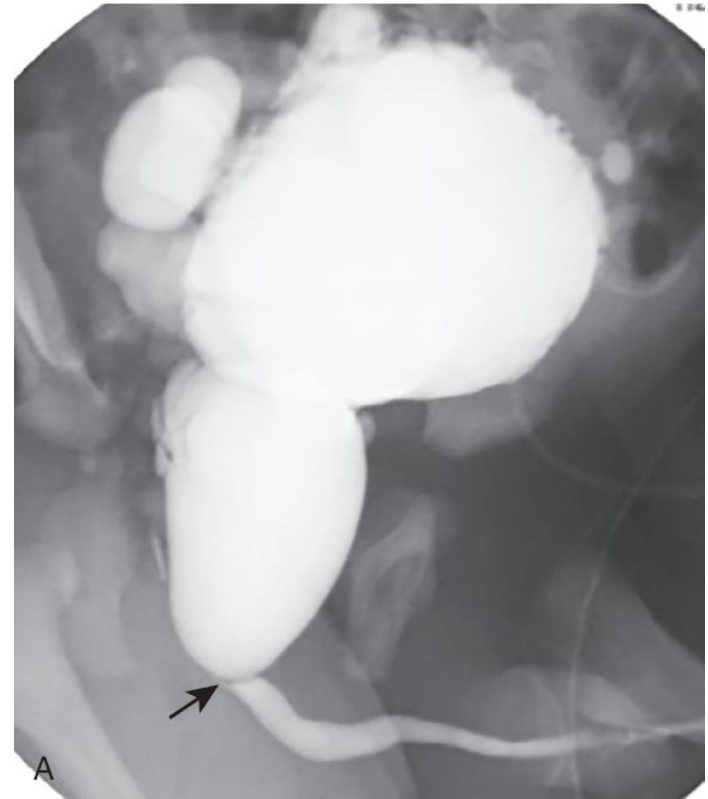- Diagnóstico pré-natal
- Investigação pos-natal
 - ECO
 - CUMS
 - MAG3
 - DMSA, uroRMN



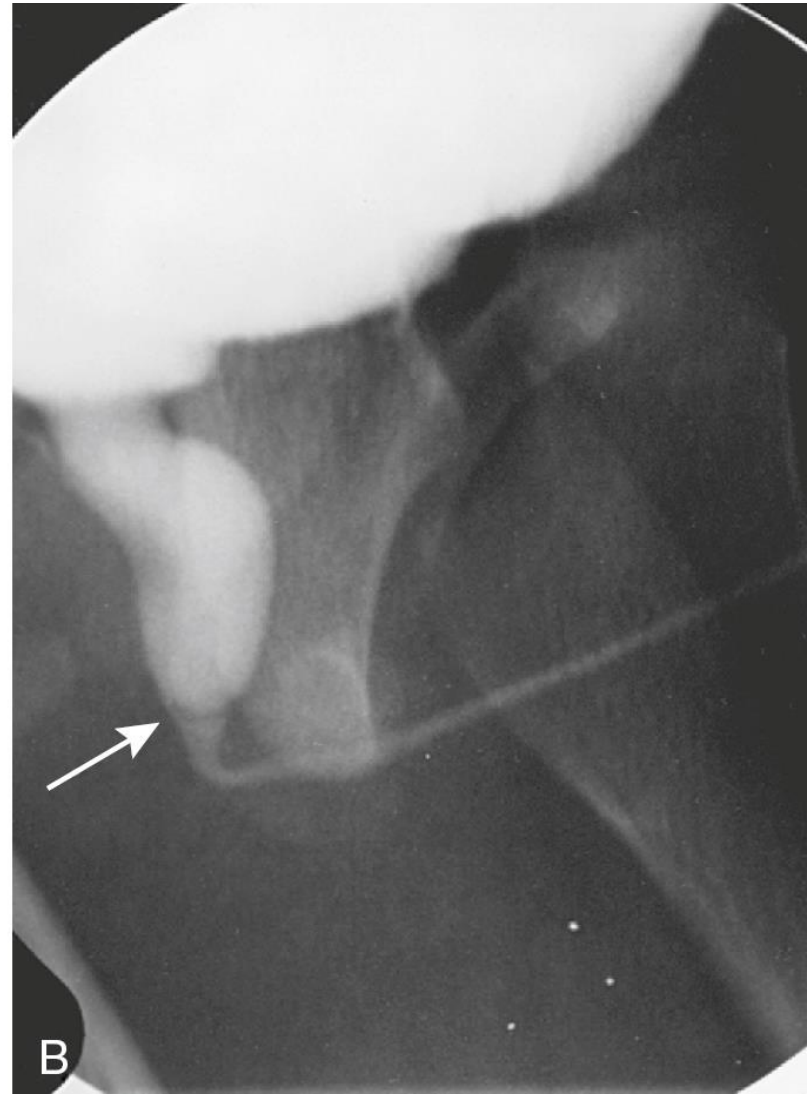
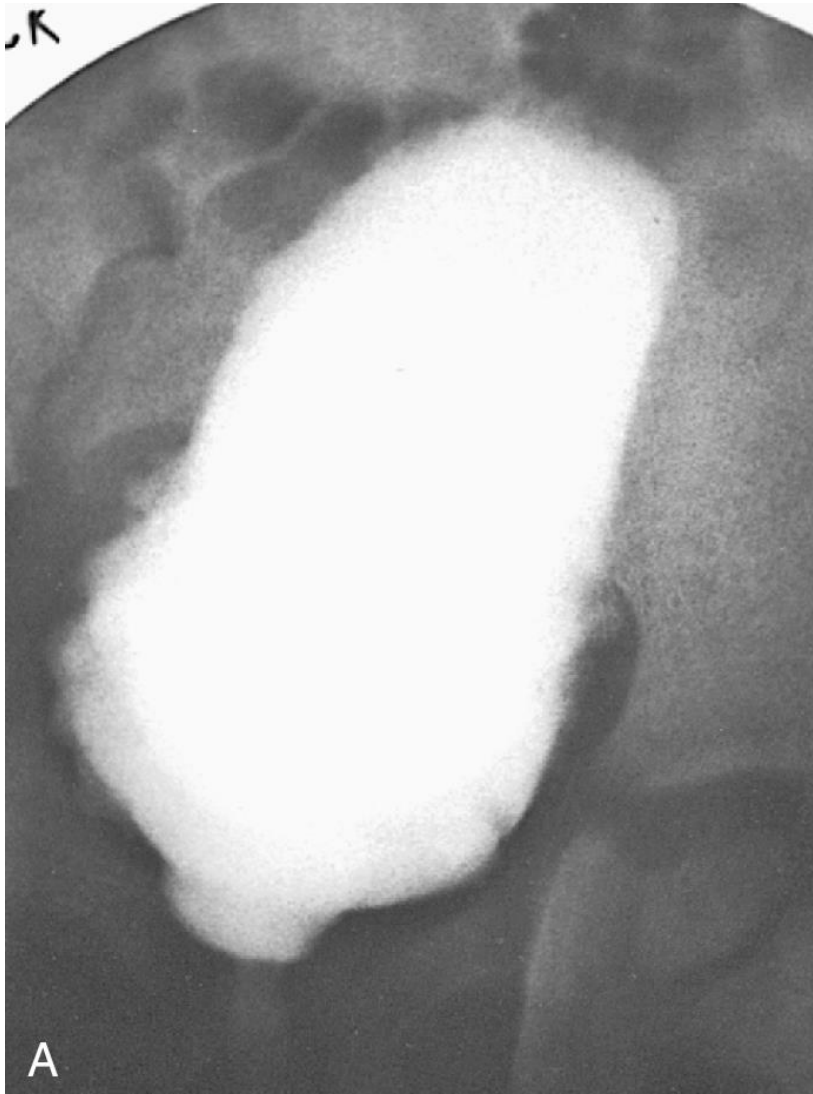Válvulas da uretra posterior



- Válvulas da uretra posterior

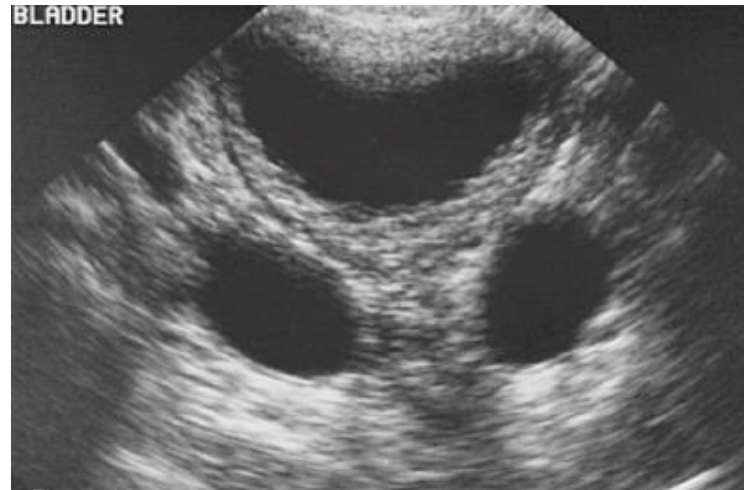

- Válvulas da uretra posterior

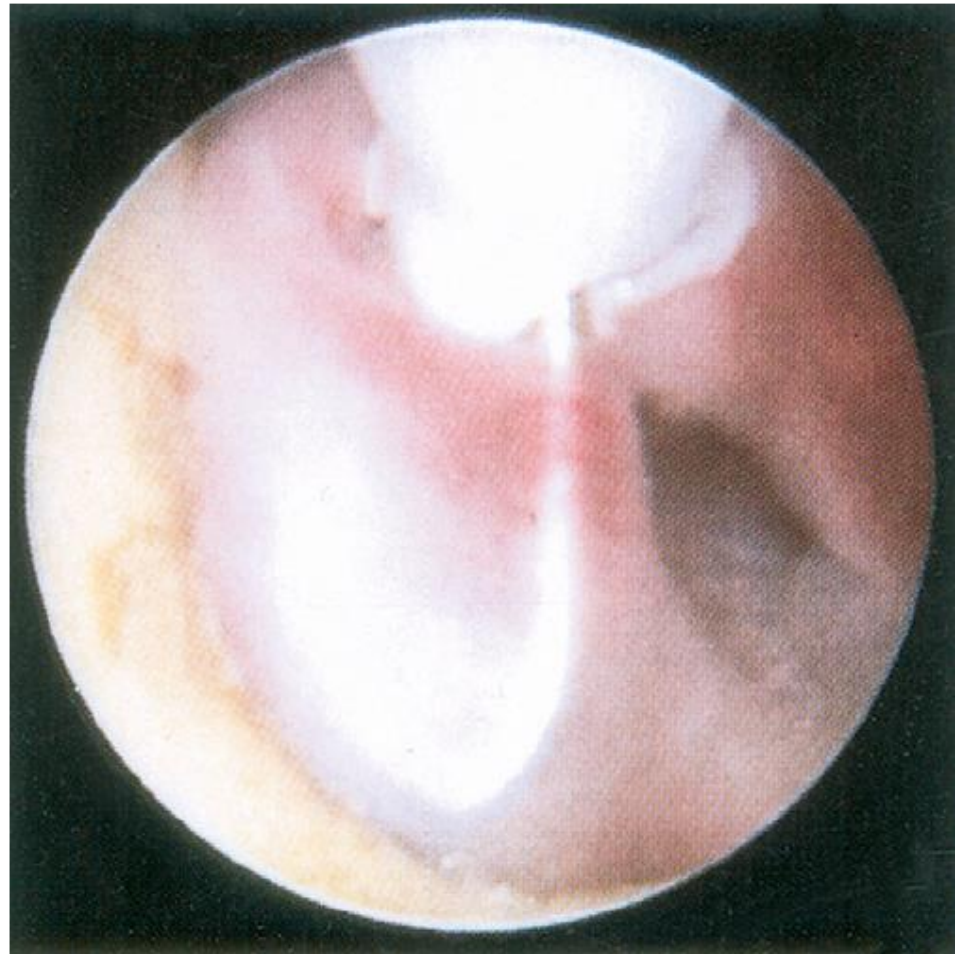

\

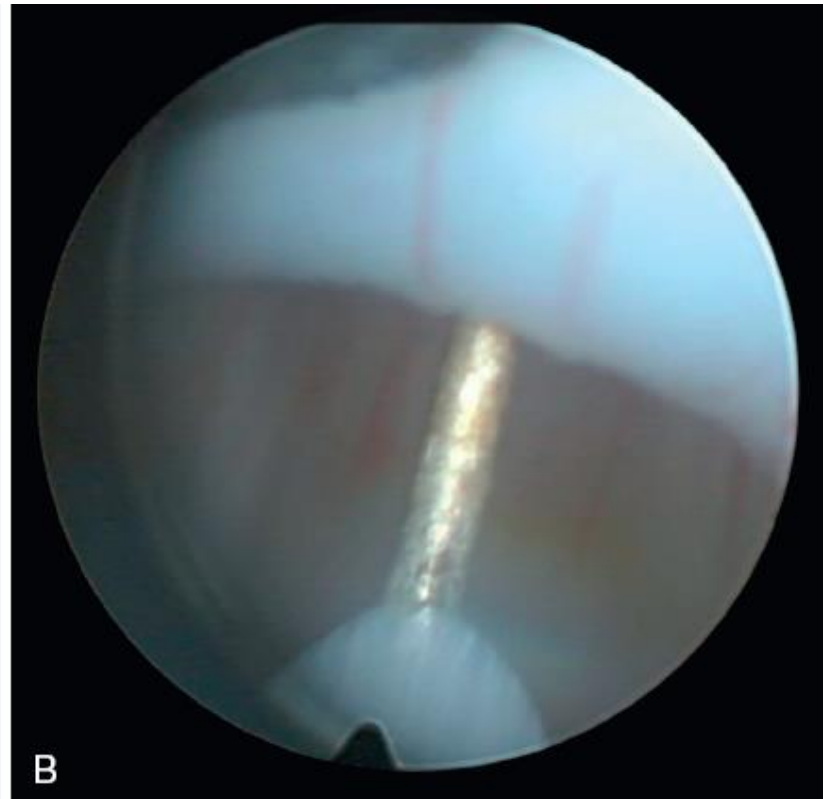
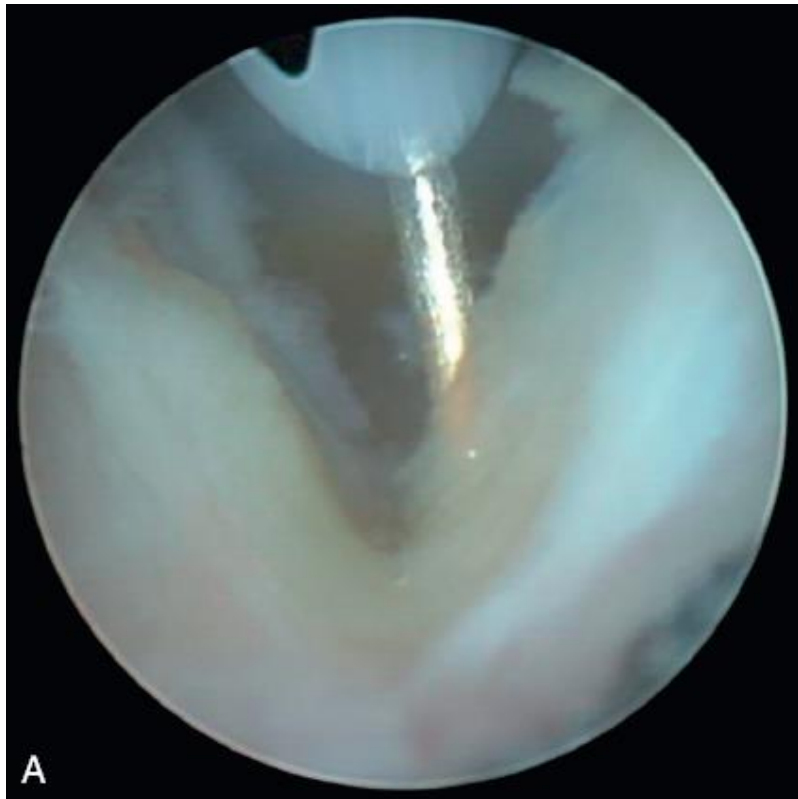- Válvulas da uretra posterior



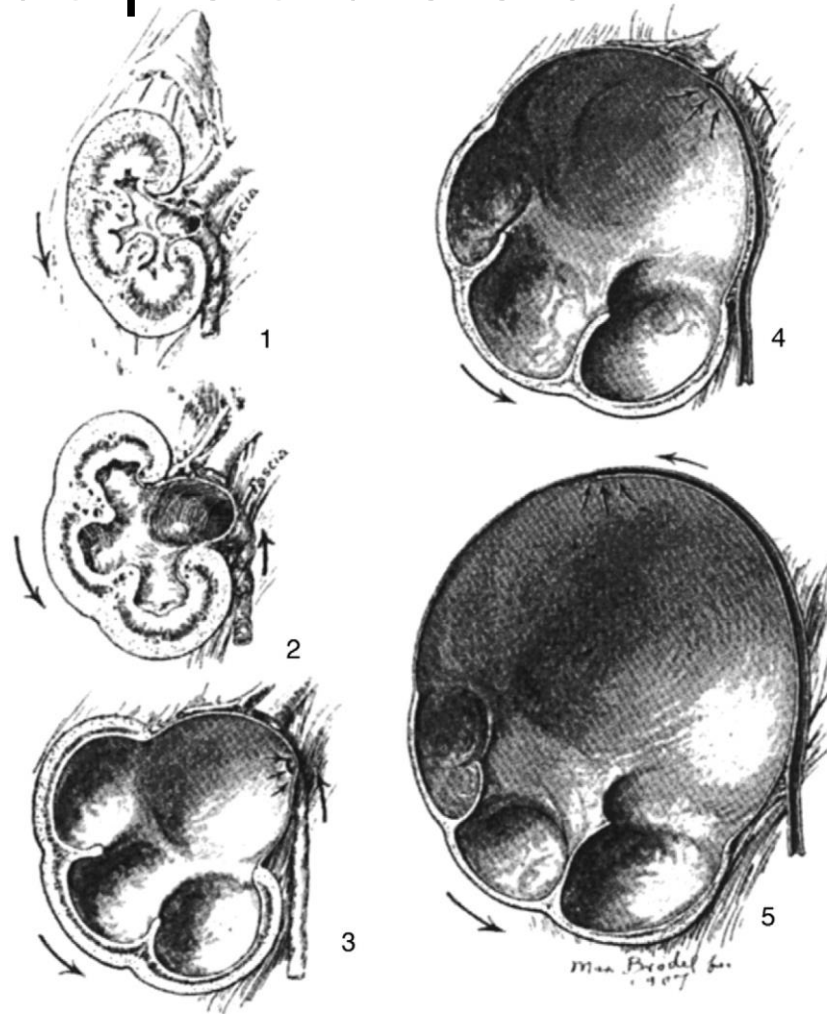
- Válvulas da uretra posterior



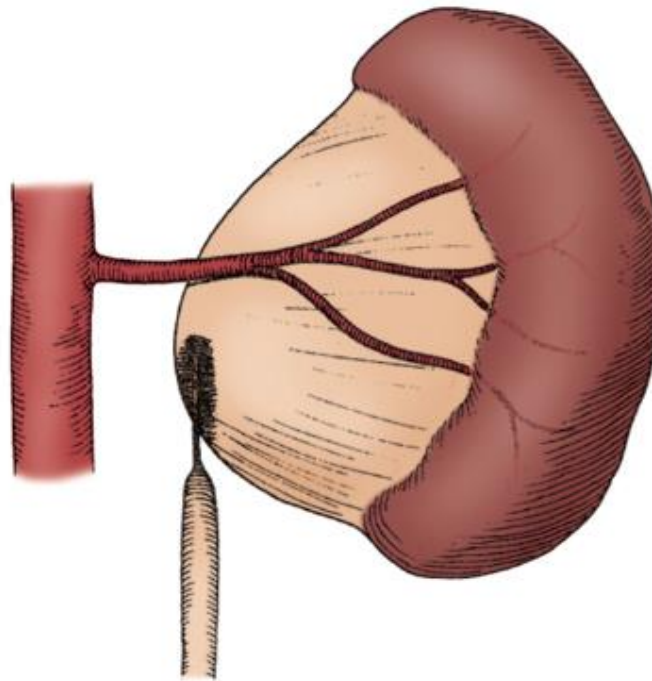
- Válvulas da uretra posterior



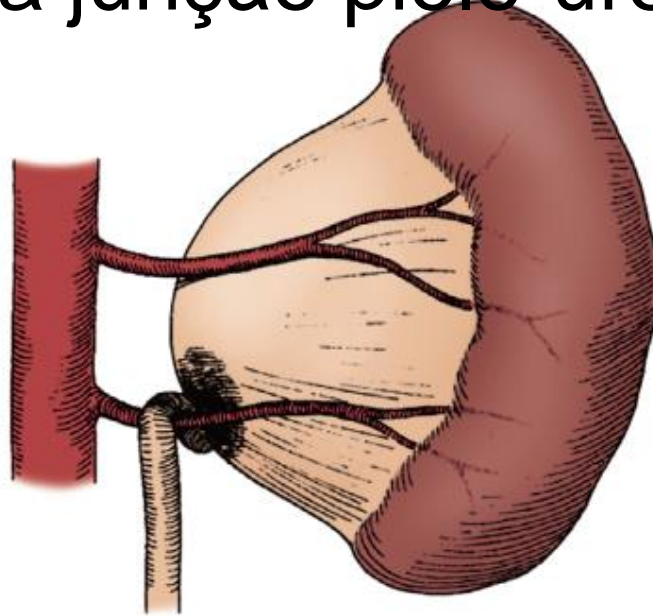
- Síndrome da junção pielo-ureteral



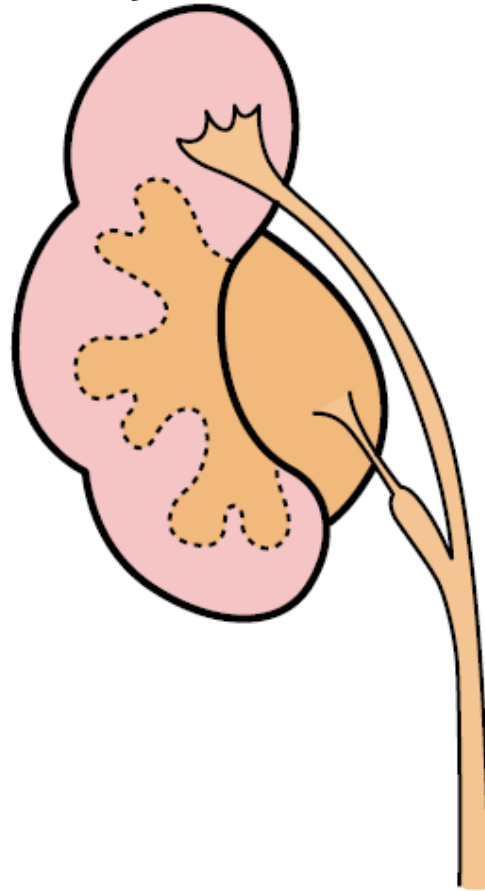
- Síndrome da junção pielo-ureteral



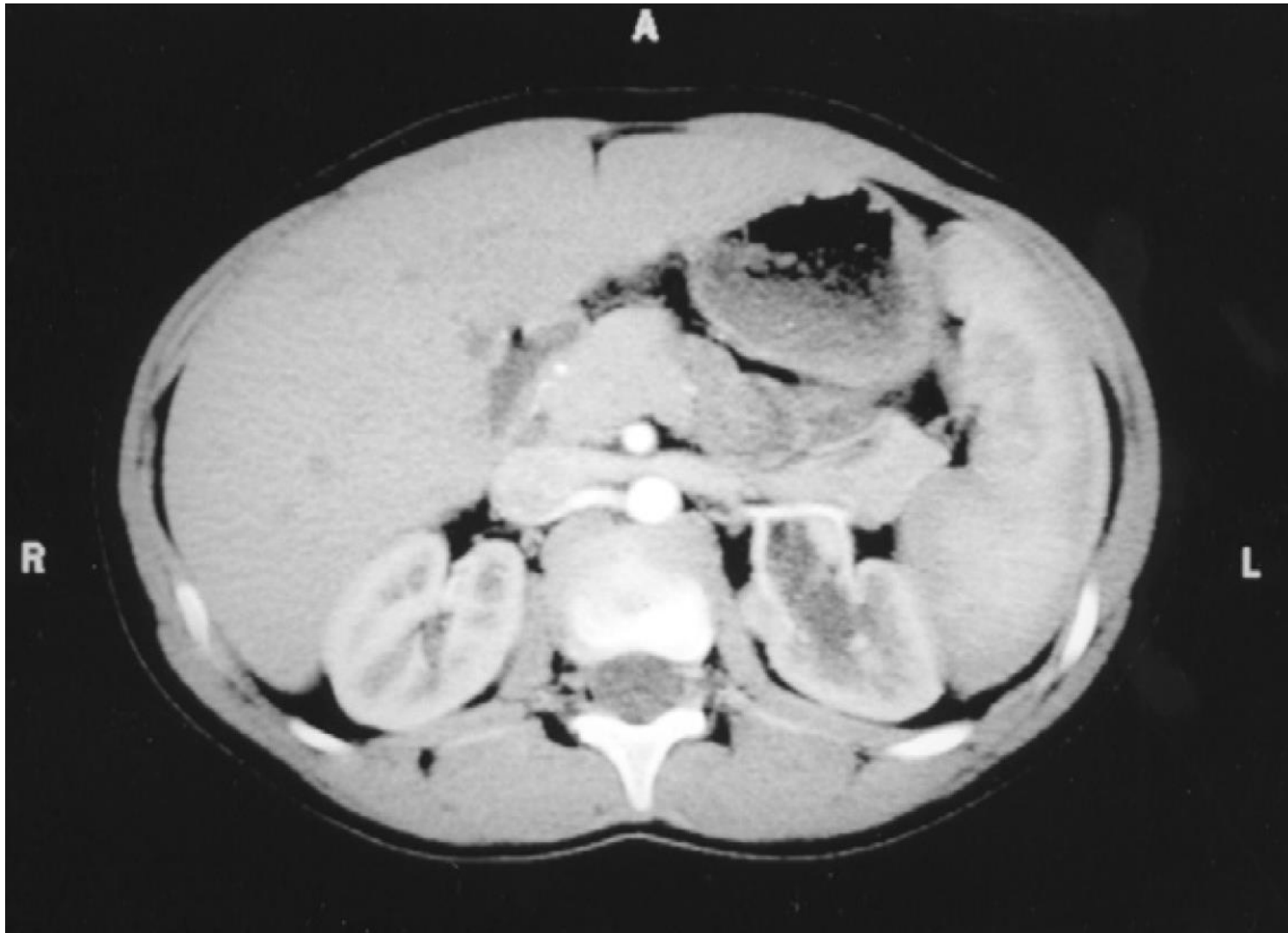
- Síndrome da junção pielo-ureteral

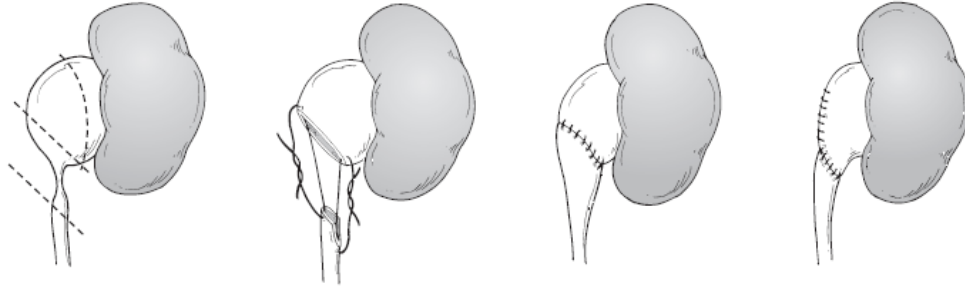


- Síndrome da junção pielo-ureteral

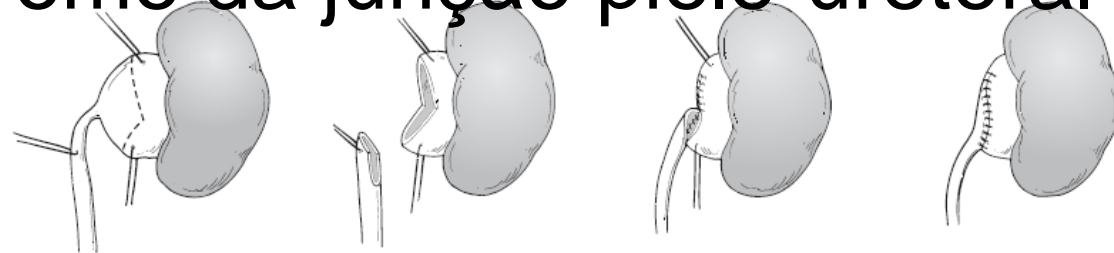


- Síndrome da junção pielo-ureteral

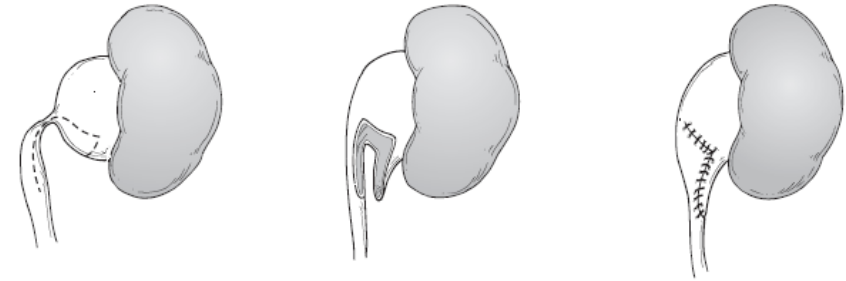




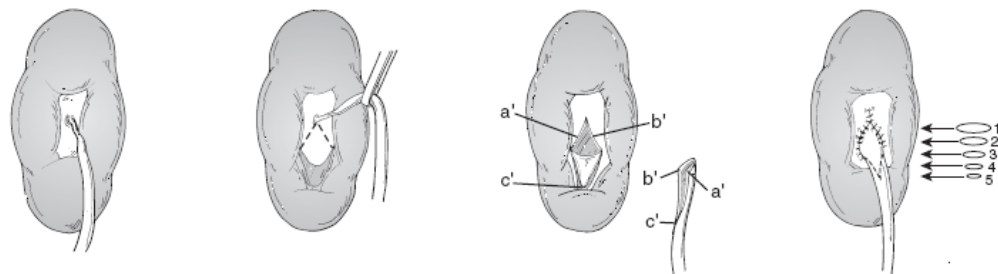
- Síndrome da junção pielo-ureteral



B

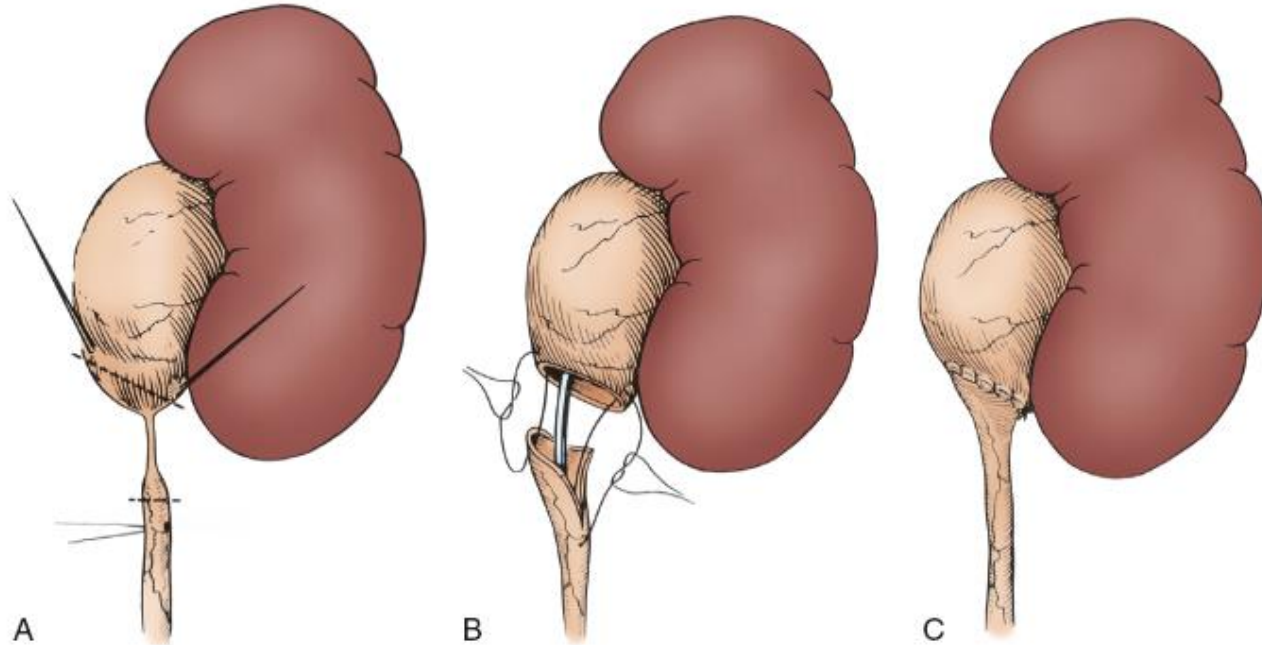


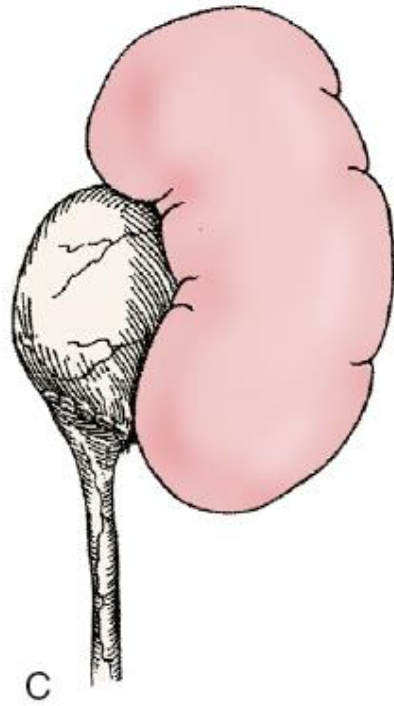
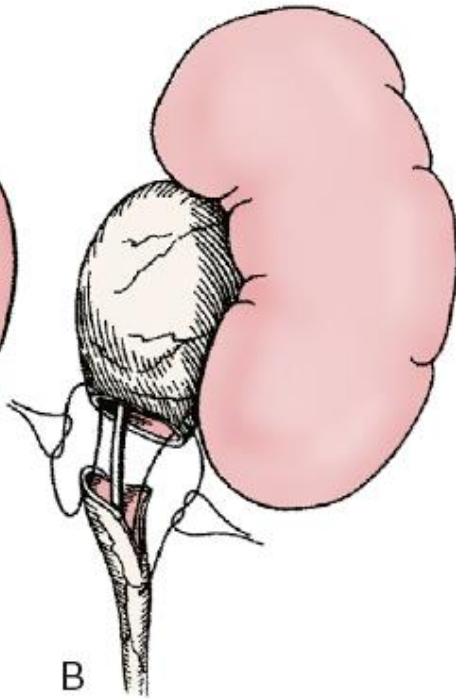
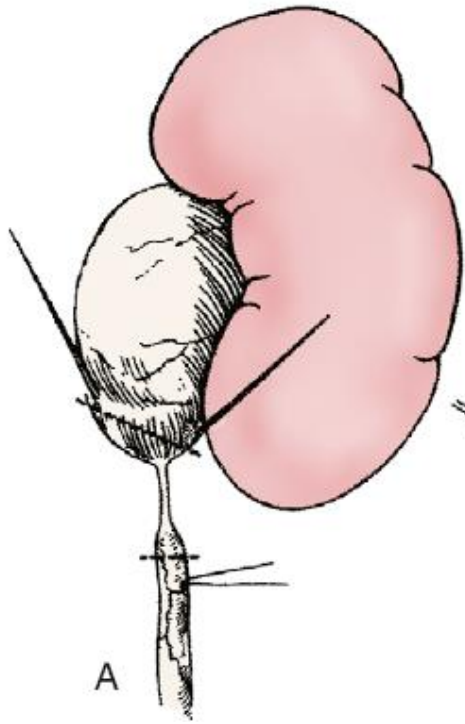
C



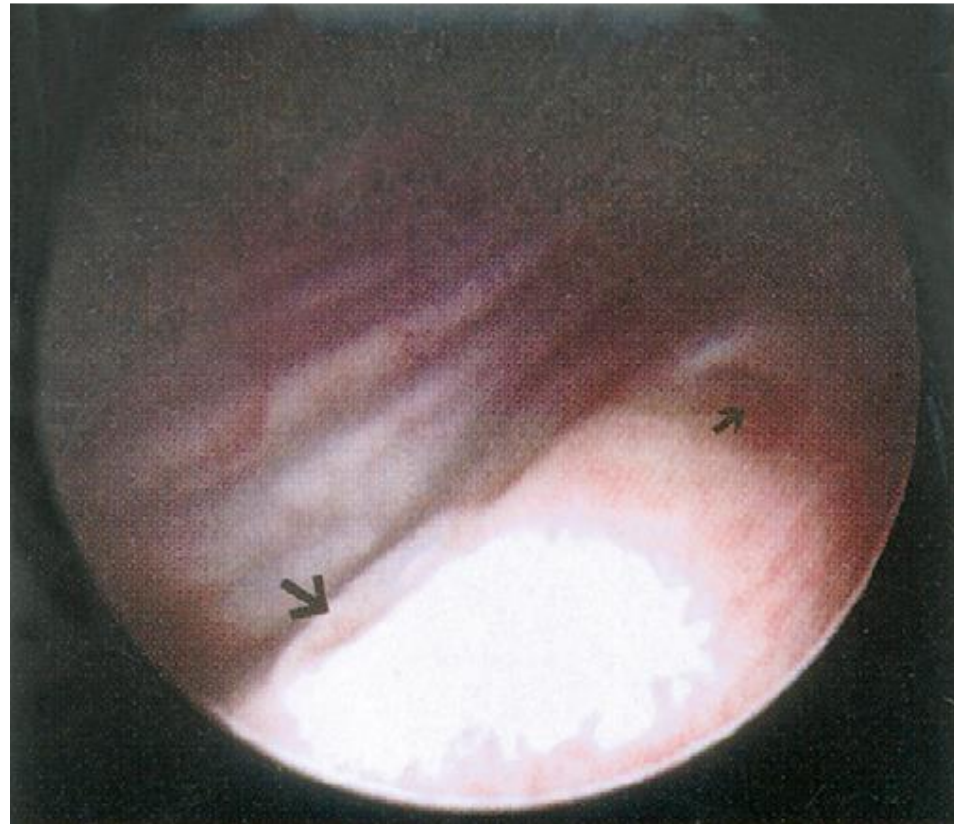D

- Síndrome da junção pielo-ureteral

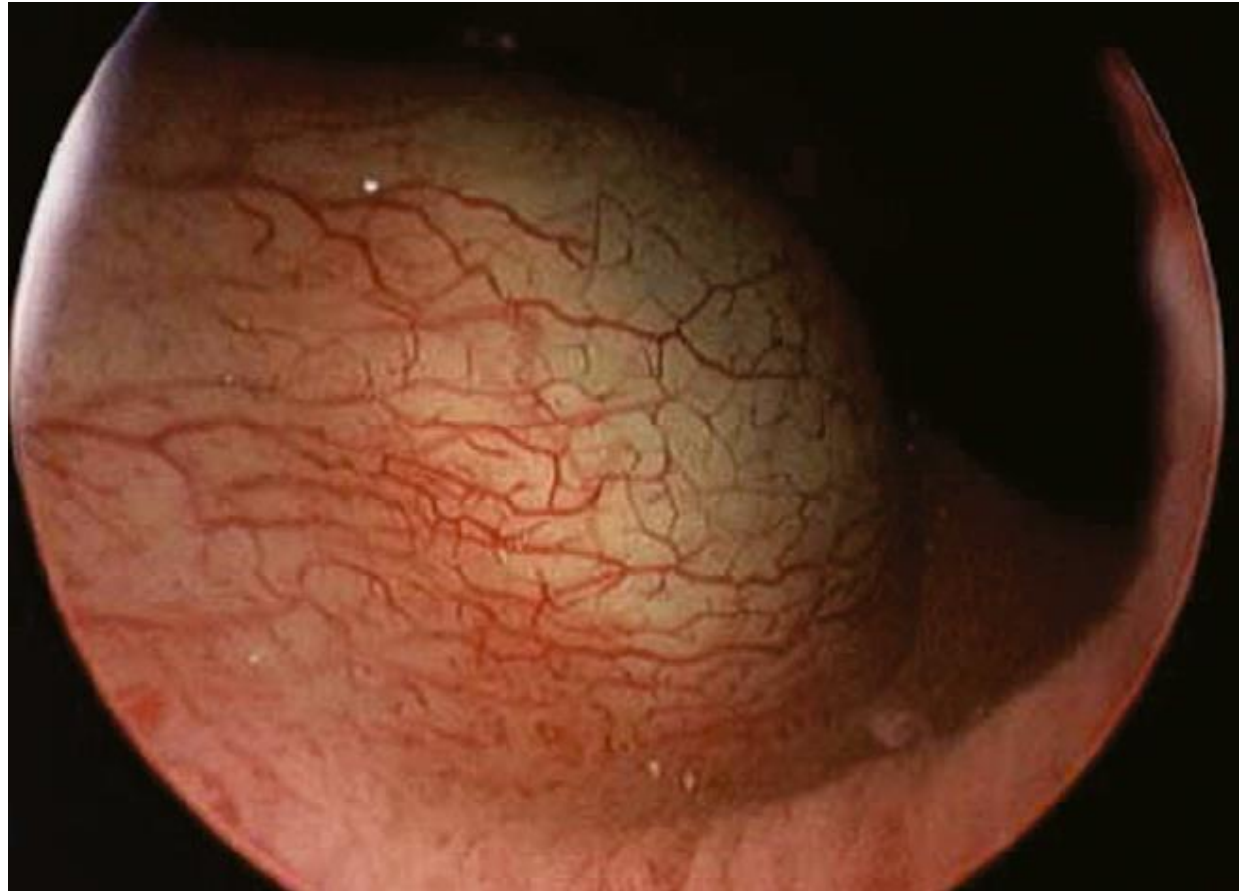



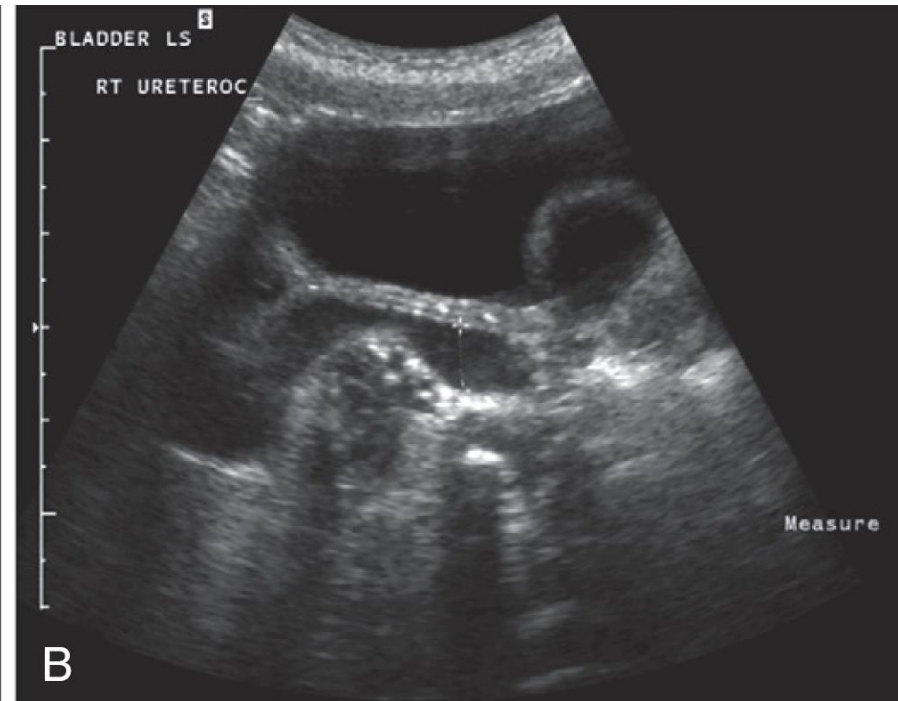
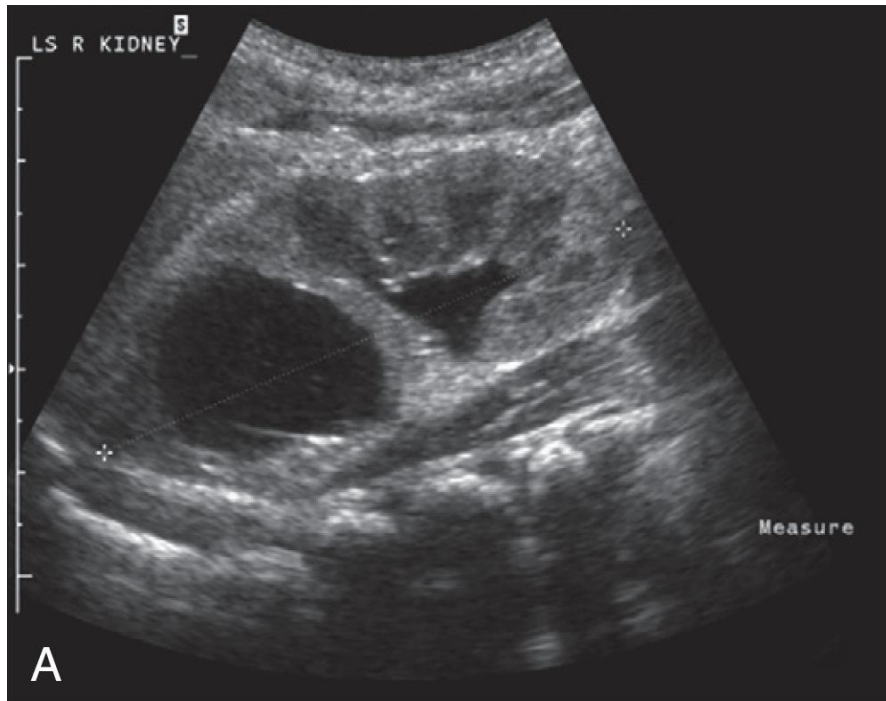
- Duplicidade uretero-pielo-calicial completa



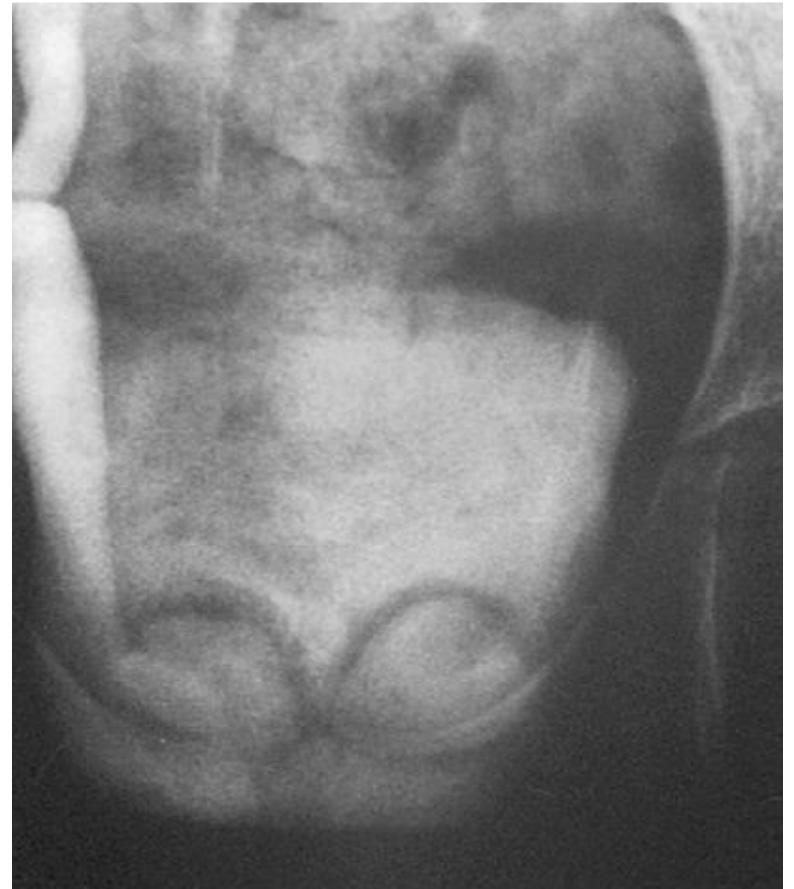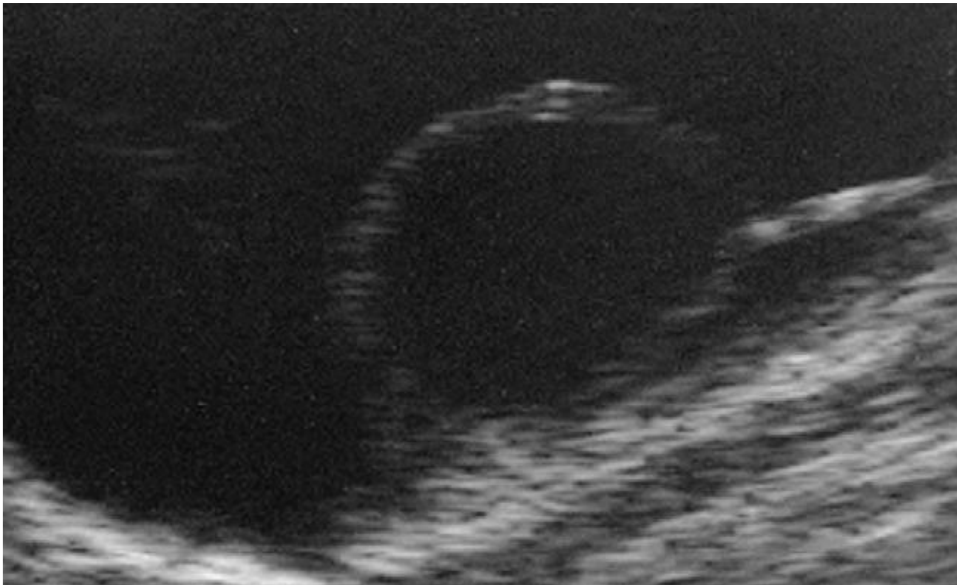
- Ureterocele



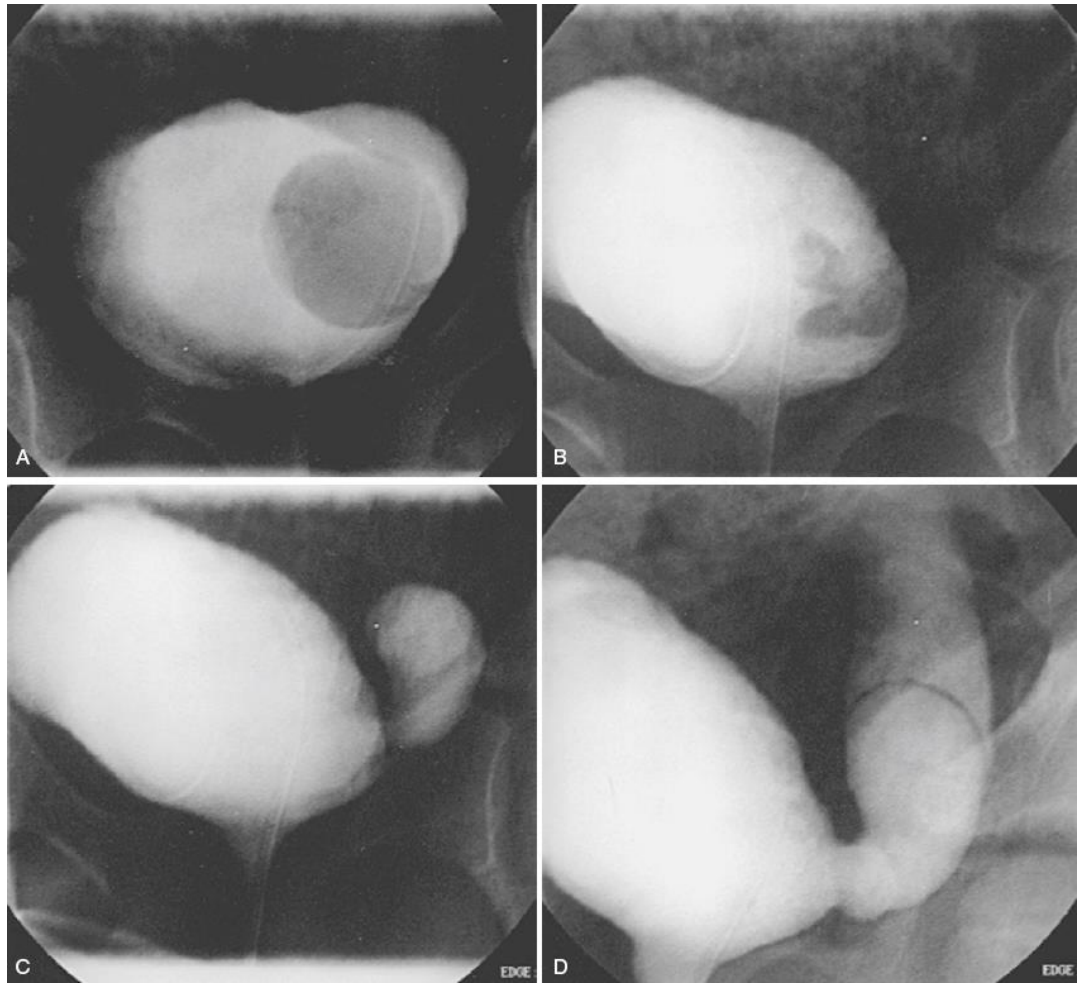
- Ureterocelo



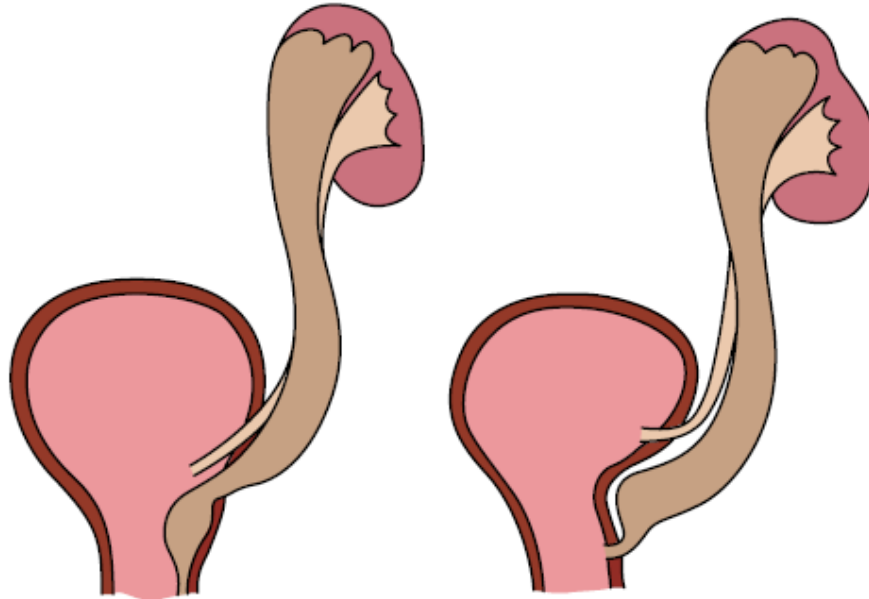
- Ureterocelo

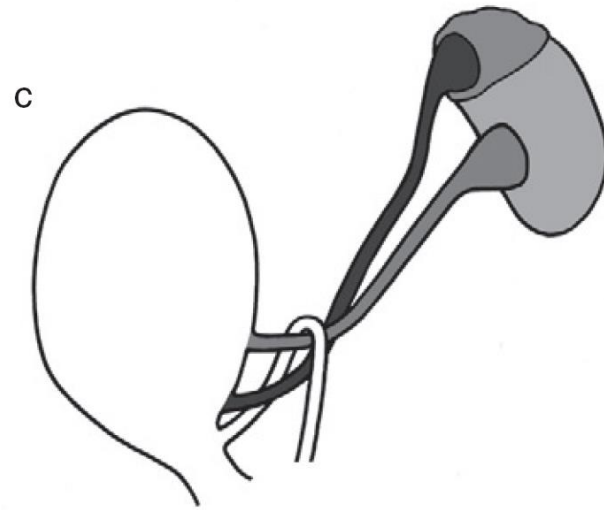
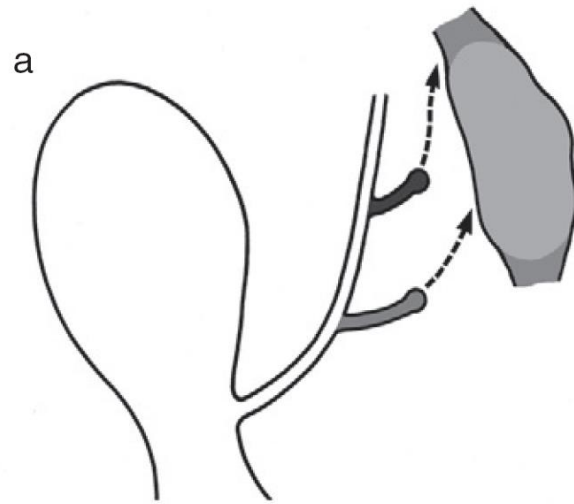


- Ureterocelo



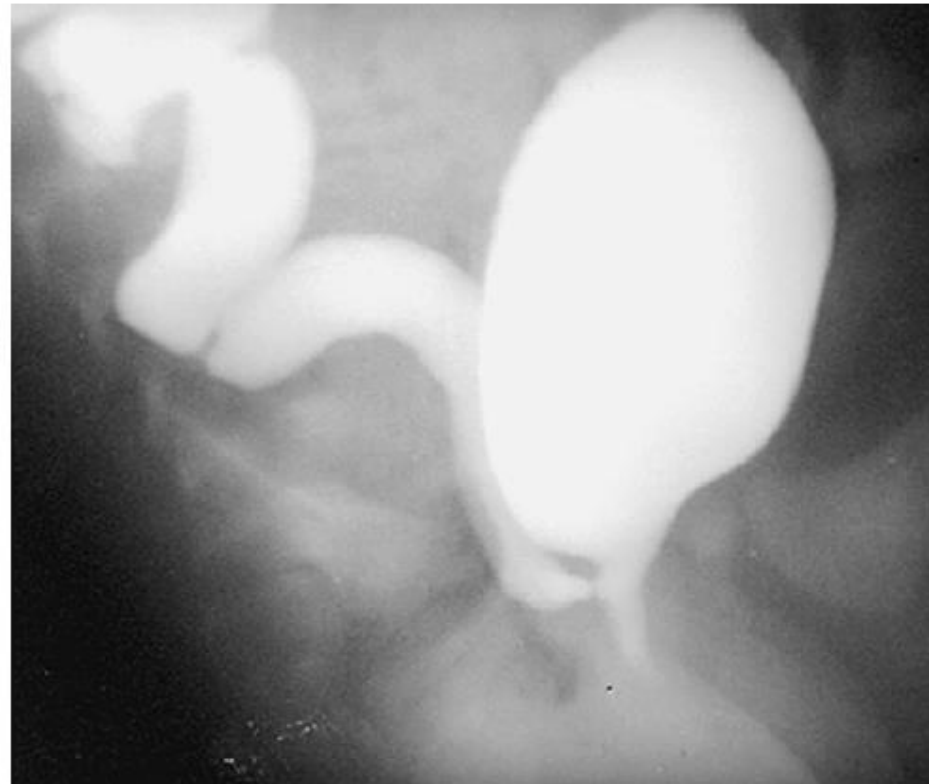
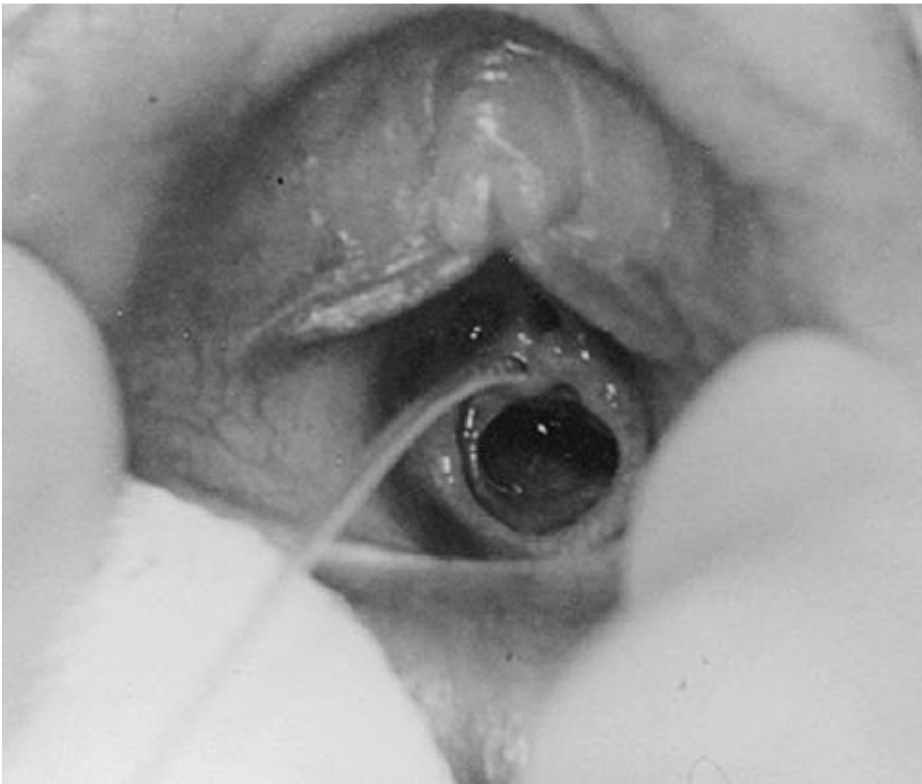
- Ureter ectópico

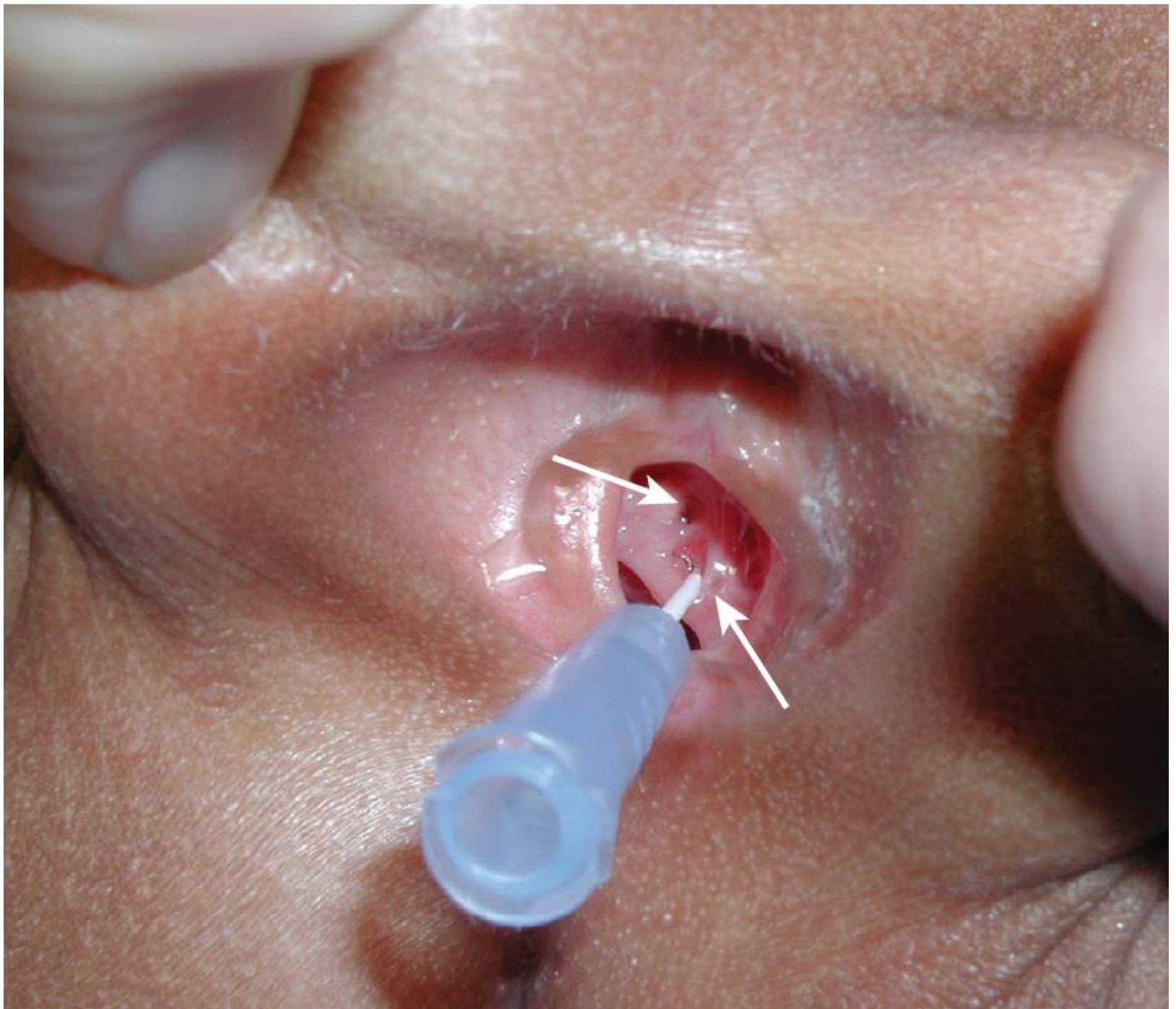


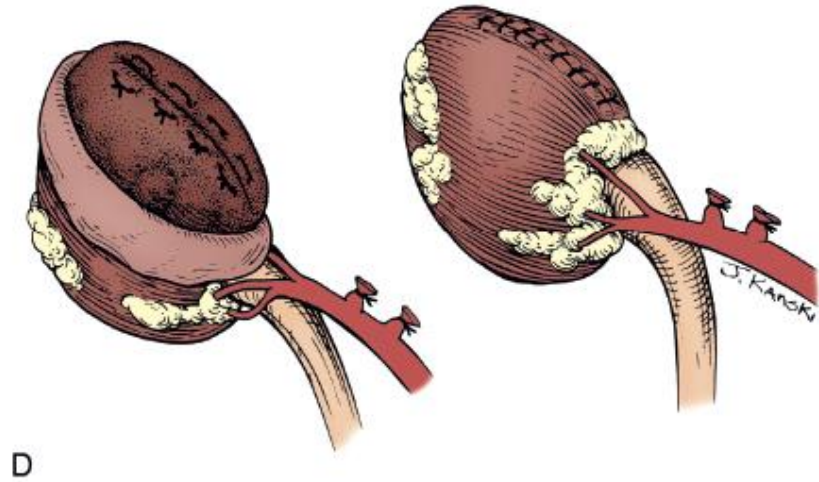
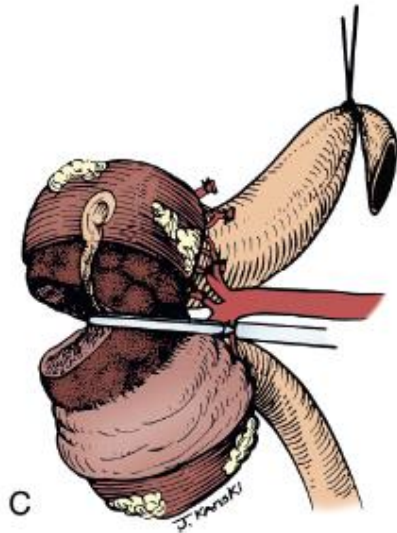
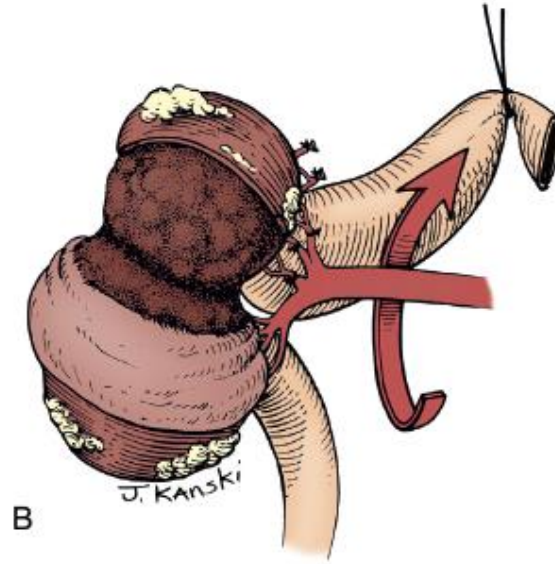
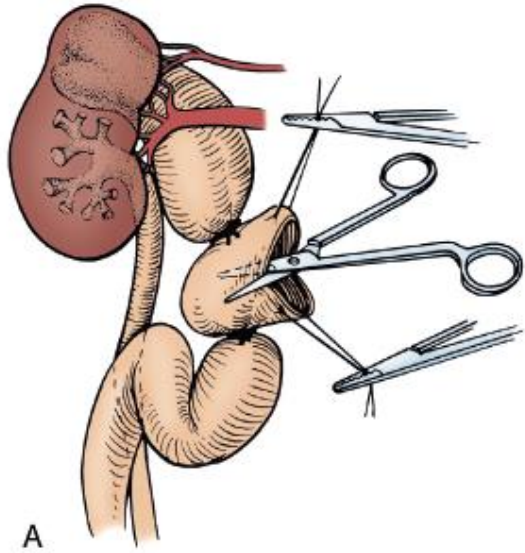


B

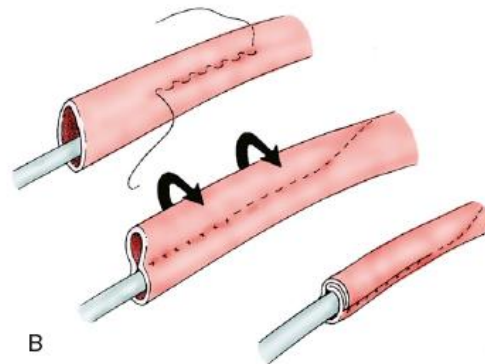
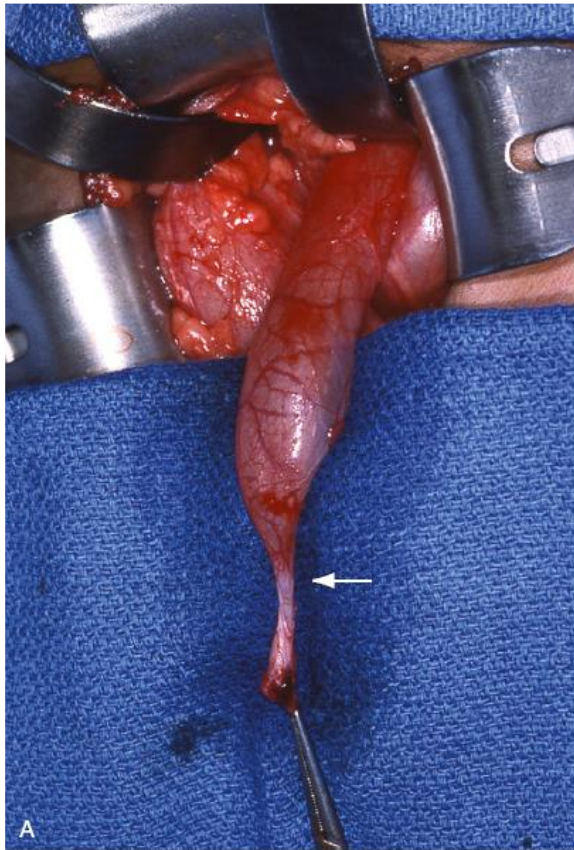
- Ureter ectópico

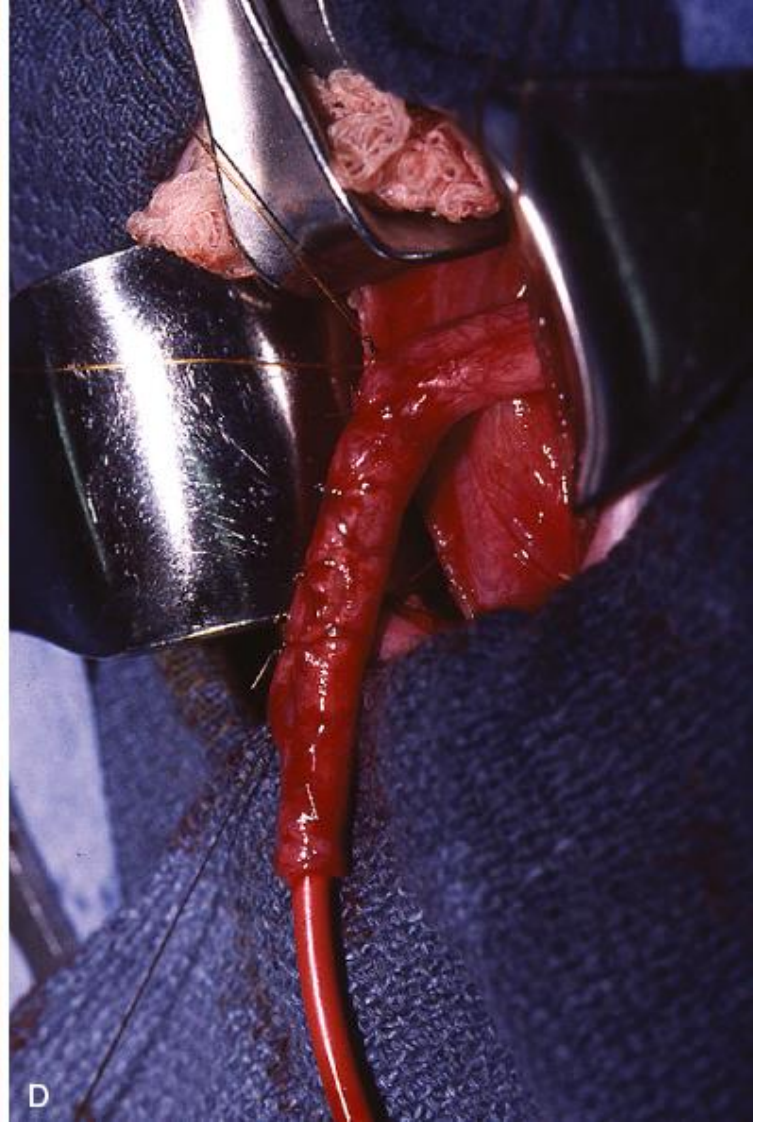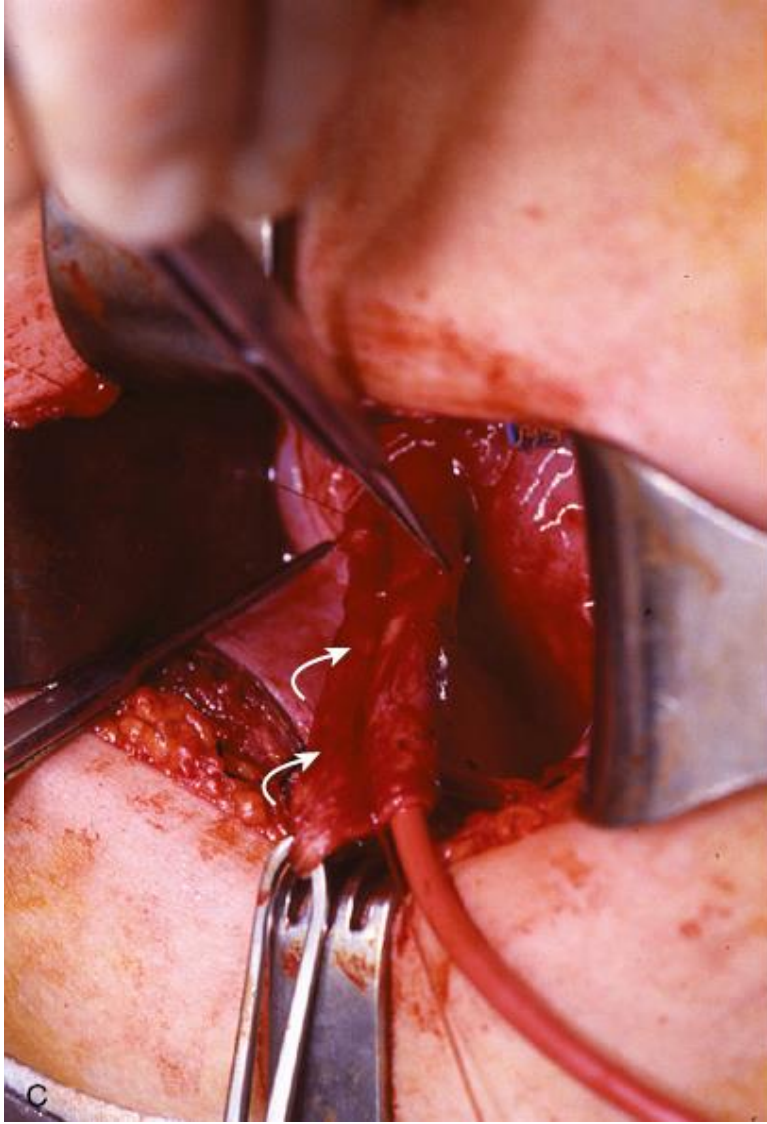


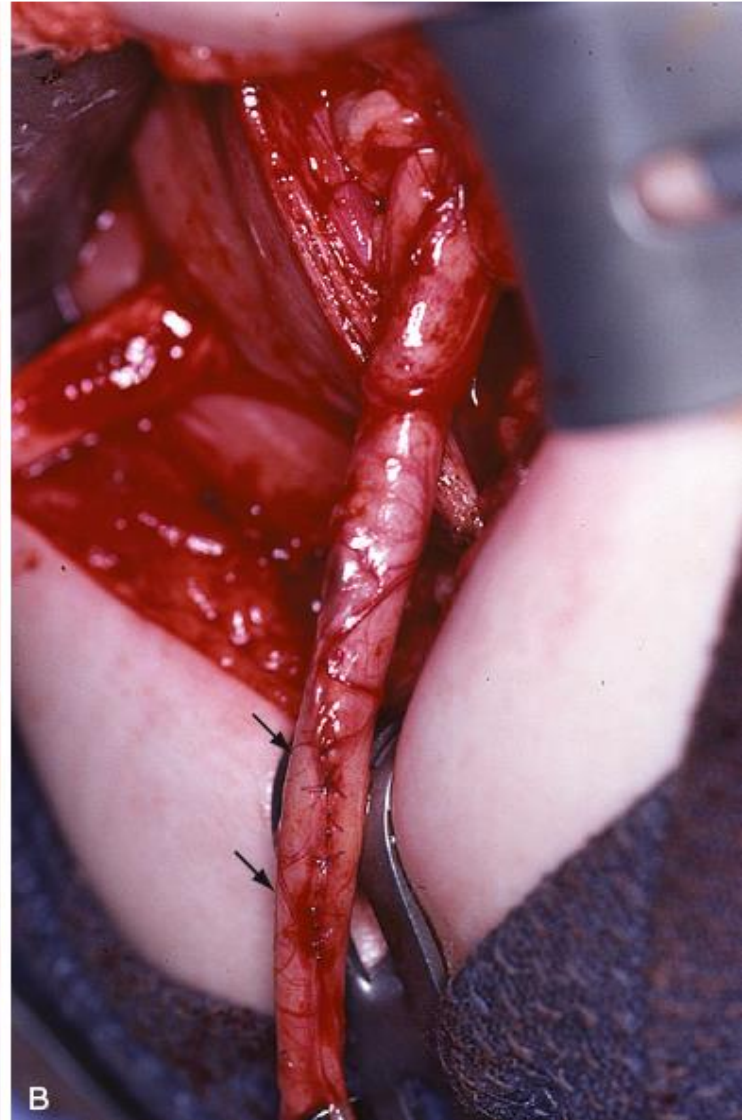
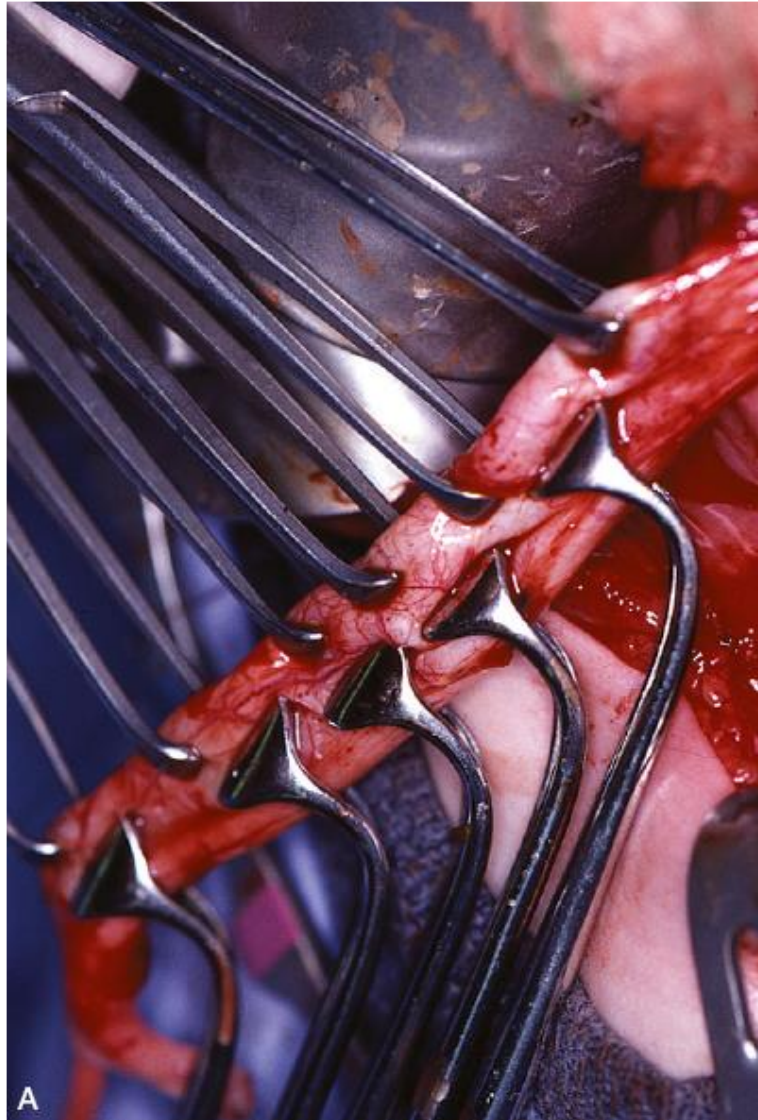




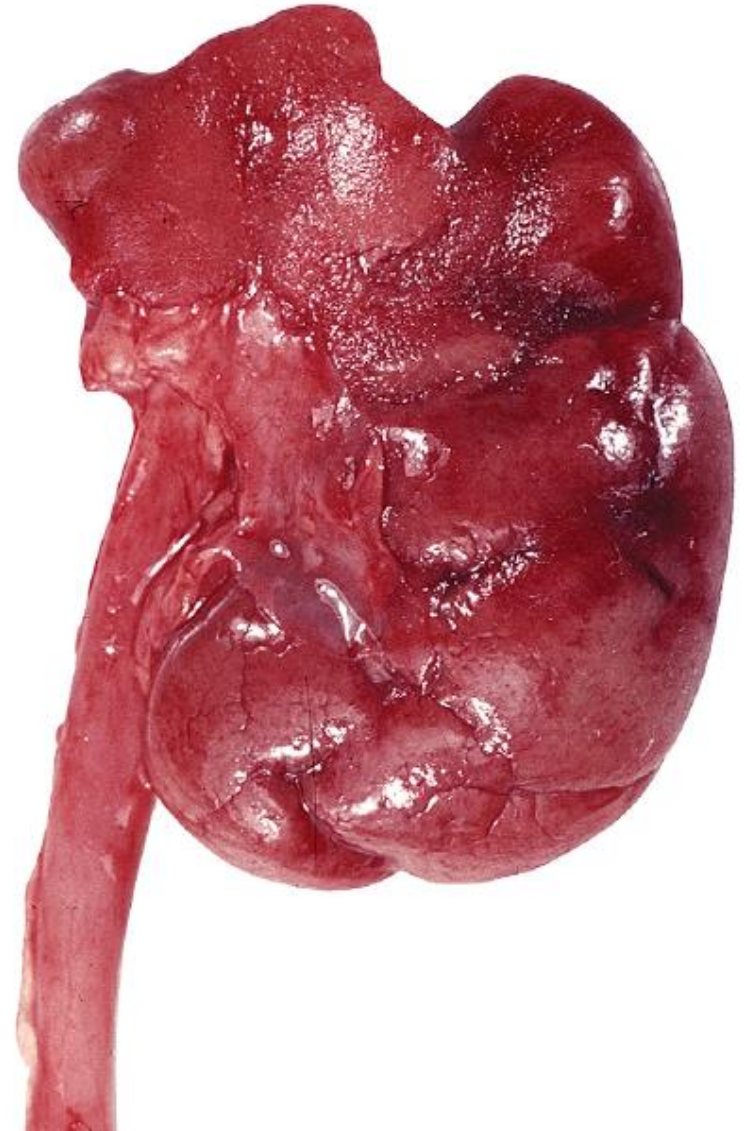
- Megaureter (obstructivo ?)



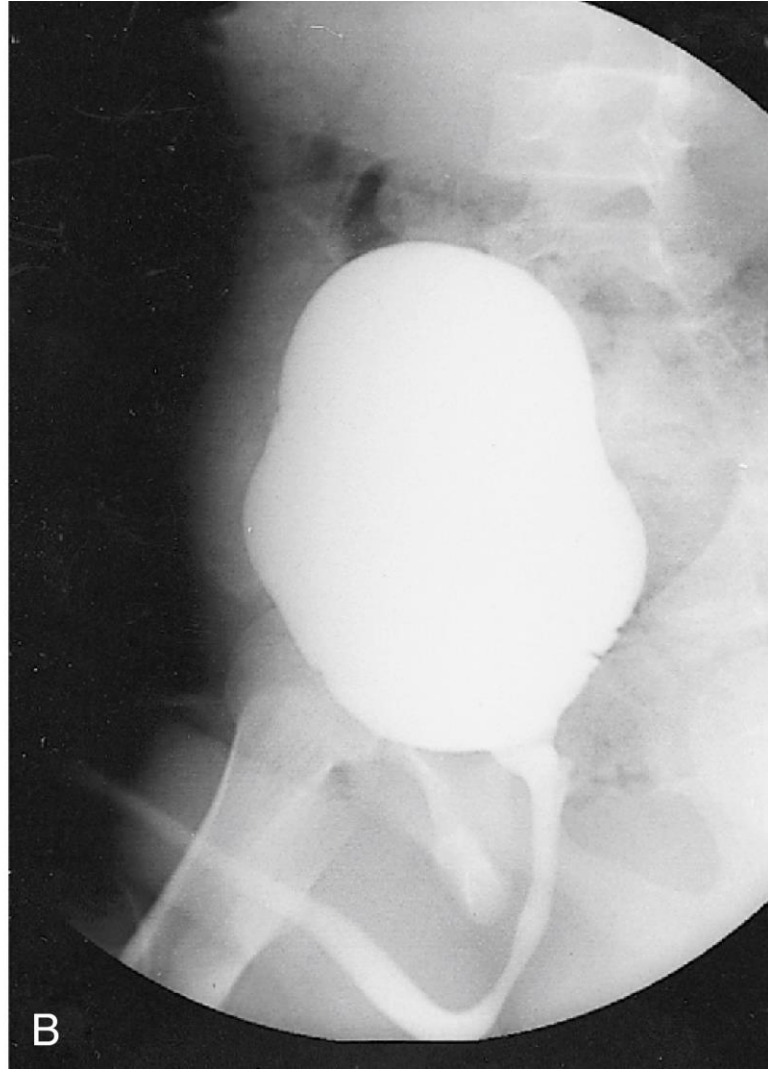
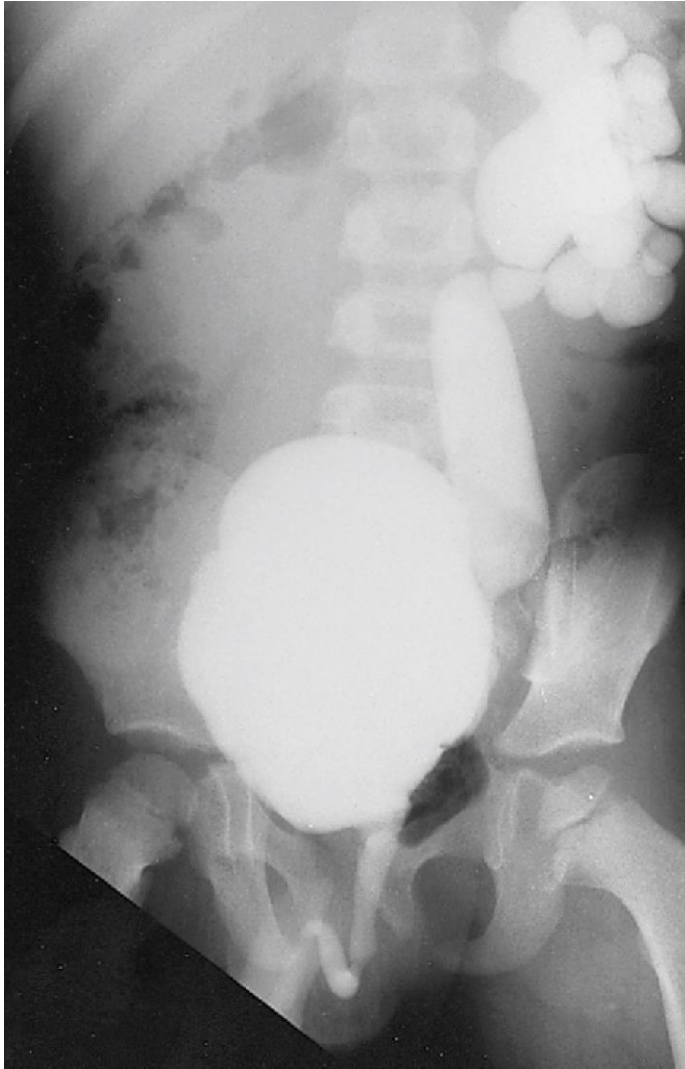



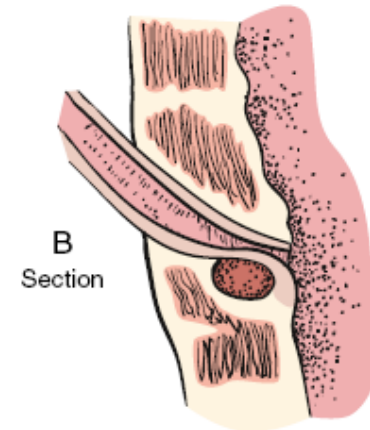
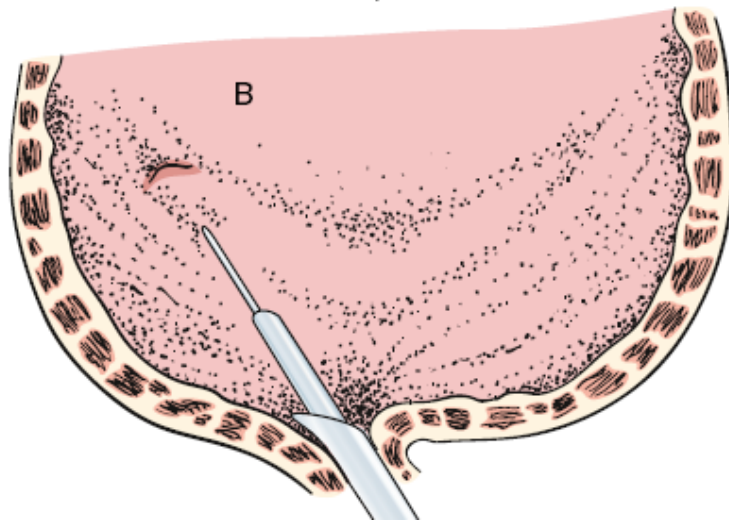
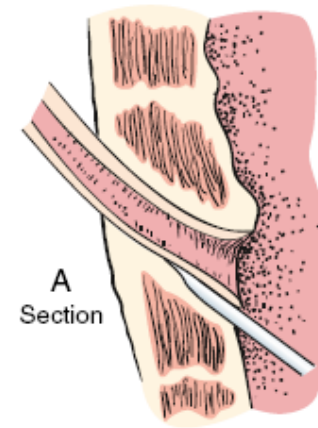
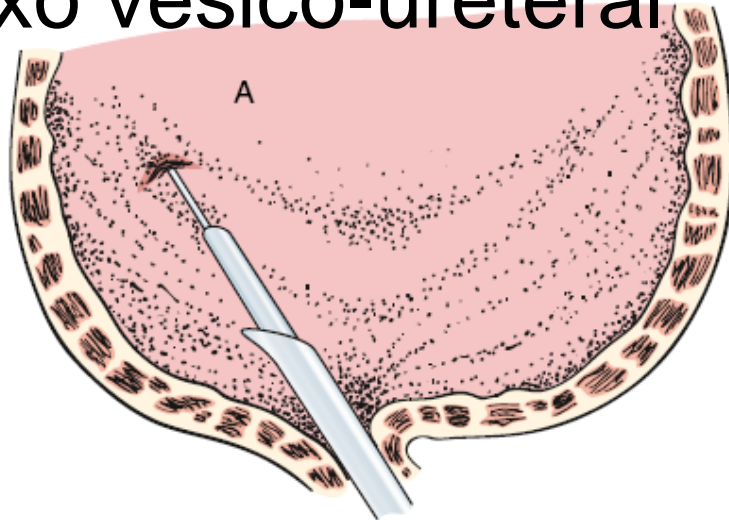
- Refluxo vesico-ureteral



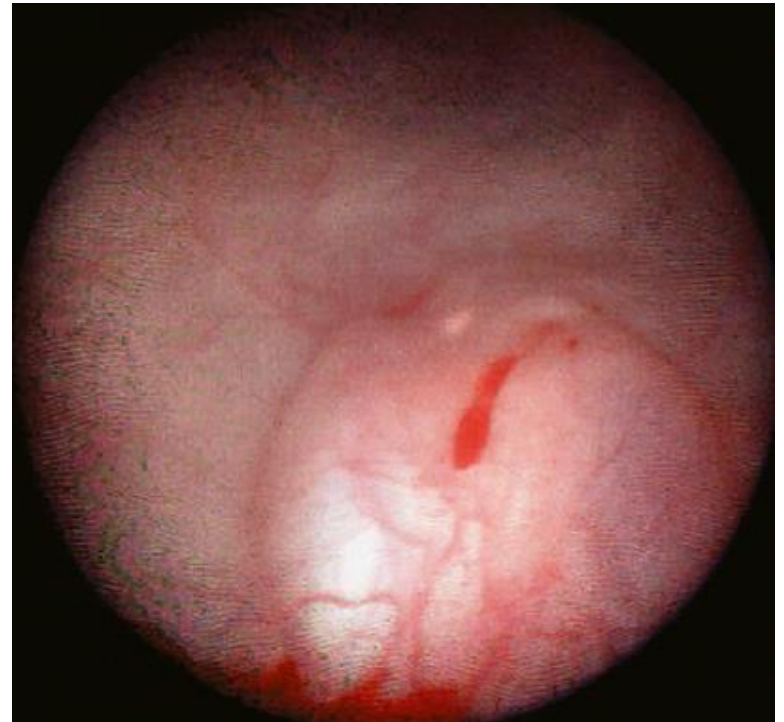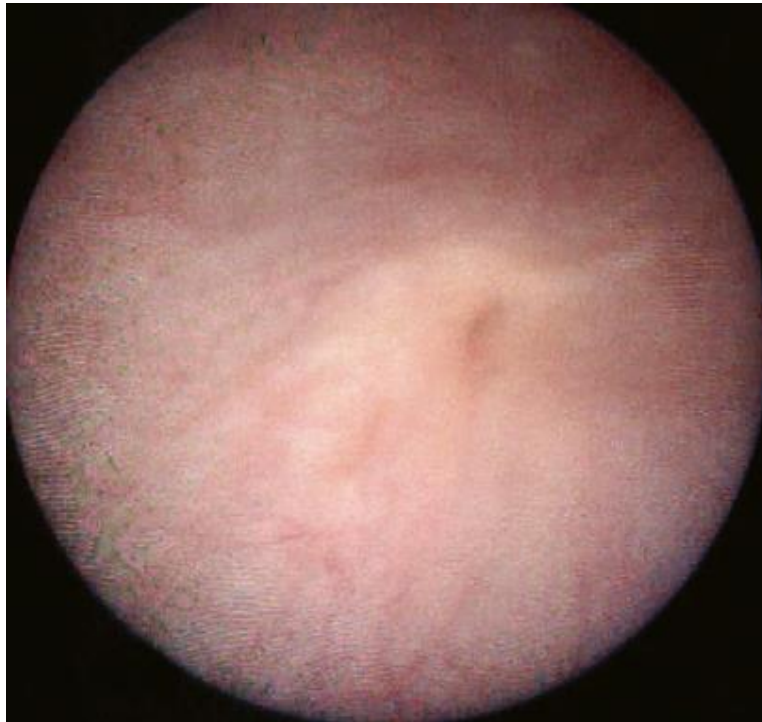- Refluxo vesico-ureteral



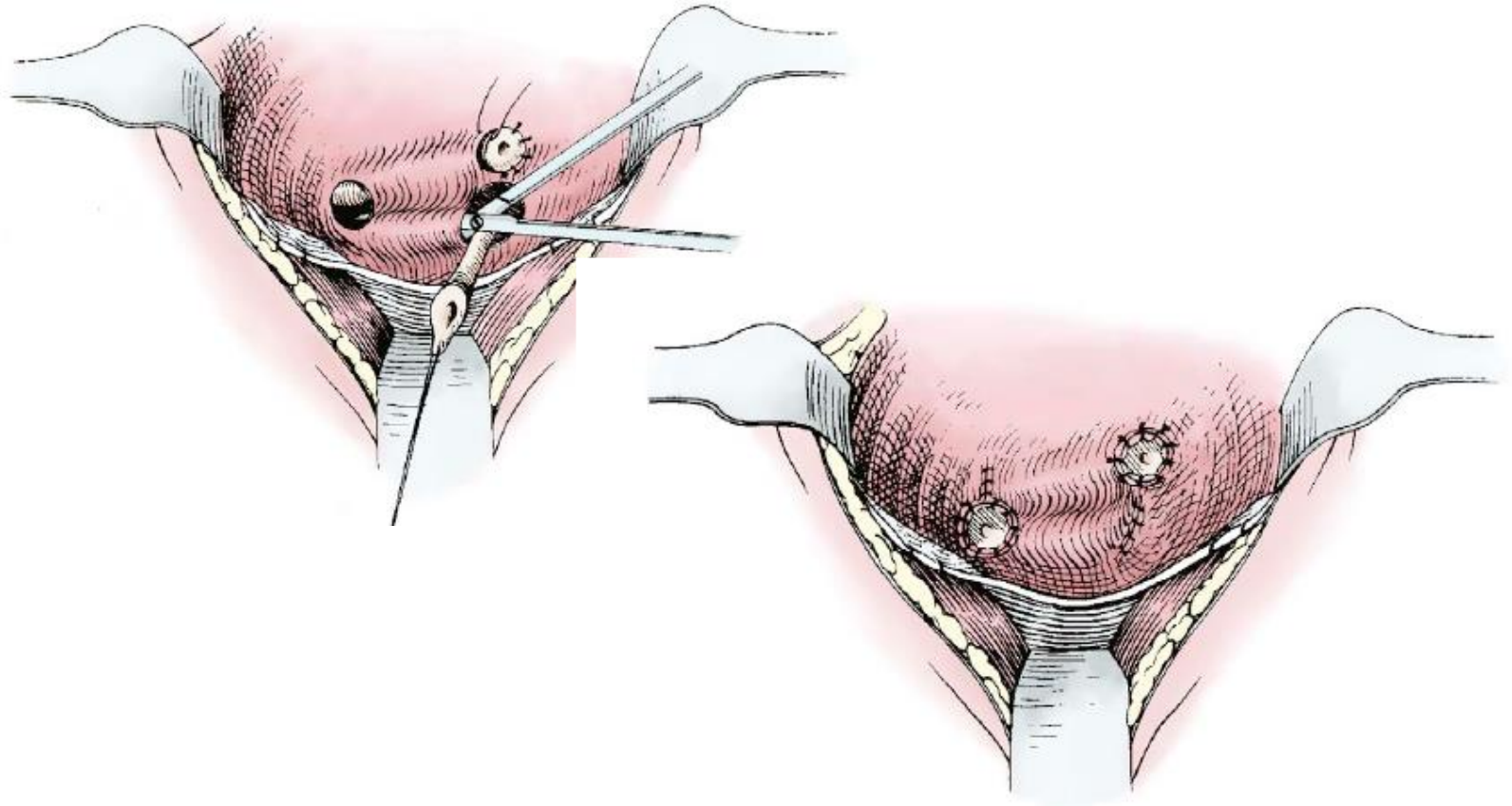
- Refluxo vesico-ureteral



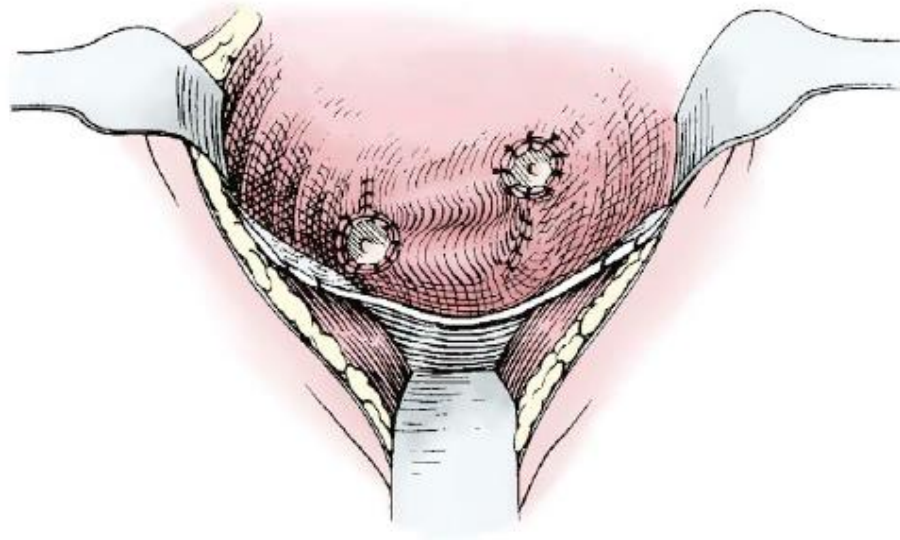
Refluxo vesico-ureteral

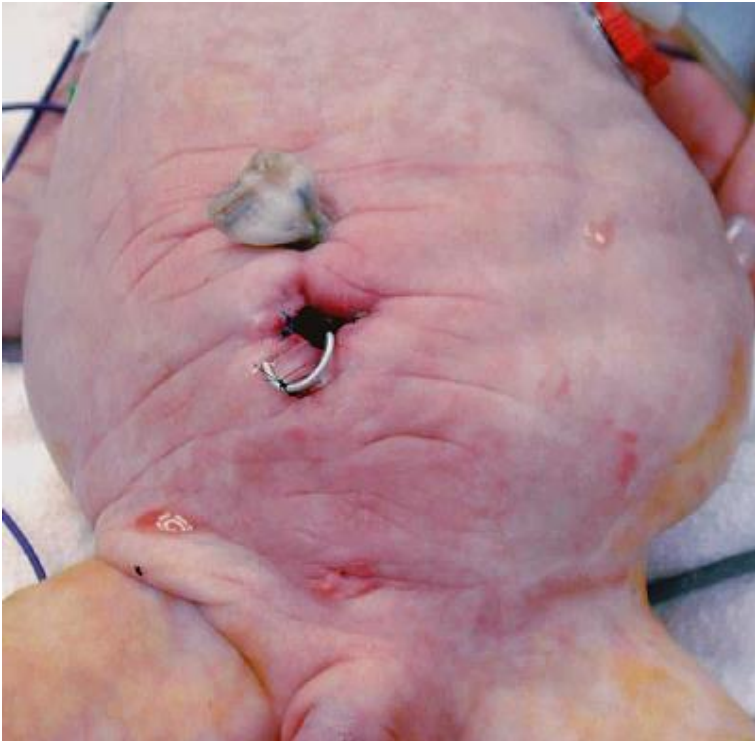


- Refluxo vesico-ureteral



- Refluxo vesico-ureteral





- **Resumo**
 - Válvulas da uretra posterior
 - Resseção endoscópica
 - Síndrome da junção pieloureteral
 - Ureteropieloplastia
 - Ureterocelo
 - Punção endoscópica
 - Nefrectomia polar superior
 - Reimplantação UV, reconstrução parede vesical.
 - Ureter ectópico
 - Nefrectomia polar superior
 - Nefrectomia
 - Reimplantação UV
 - Megaureter
 - Reimplantação UV com modelagem do ureter distal
 - RVU
 - Tratamento conservador
 - Tratamento endoscópico.
 - Reimplantação UV



D-KMAS

30